



Cranio-maxillofacial

# Implant Directions®

Vol.15 N° 4

December 2021

English Edition



CASE REPORT:  
CONSIDERATIONS REGARDING IMPLANTOLOGICAL TREATMENT  
IN PATIENTS WITH AGGRESSIVE PERIODONTAL INVOLVEMENT

S. IHDE, A. IHDE

ISSN 1864-1199 / e-ISSN 1864-1237

# OFFPRINT

Published by IF Publishing, Germany



The Foundation of Knowledge

## Editorial board

### Managing editor

Dr. Łukasz Pałka  
regmed.klinika@gmail.com

Dr. Vivek Gaur  
drvivekgaur@yahoo.co.in

### Coordinating editor

Joanna Dołbaczuk  
j.dolbaczuk@gmail.com

### Editorial board (in alphabetic order)

Dr. Muhammad Alobayat, Palestine  
Dr. Pablo Diaz, Ecuador  
Dr. Anita Doshi, India  
Dr. Marcos Daniel Gonzales, Colombia  
Dr. Georg Huber, Germany  
Prof. Dr. Vitomir S. Konstantinovic, Serbia  
Dr. Alexander Lazarov, Bulgaria  
Dr. Igor Lell, Germany  
Dr. Valeri Lysenko, Ukraine  
Dr. Werner Mander, Spain  
Dr. Juri Mitrushenkov, Russia  
Dr. Mahendra Perumal, India  
Dr. Andrii Shmojlov, Russia  
Prof. Dr. Jan Vares, Ukraine

### Evidence reports and Critical Appraisals

IF Research & Evidence Dept.

### Annual Subscription

Euro 2.800

### Copyright

Copyright ©2006 - 2021 by  
International Implant Foundation  
DE- 80802 Munich / Germany  
www.implantfoundation.org

### Contact

publishing@implantfoundation.org

### CMF.Impl.dir.

ISSN 1864-1199  
e-ISSN 1864-1237

## Disclaimer

### Hazards

Great care has been taken to maintain the accuracy of the information contained in this publication. However, the publisher and/or the distributor and/or the editors and/or the authors cannot be held responsible for errors or any consequences arising from the use of the information contained in this publication. The statements or opinions contained in editorials and articles in this publication are solely those of the authors thereof and not of the publisher, and/or the distributor, and/or the IIF.

The products, procedures and therapies described in this work are hazardous and are therefore only to be applied by certified and trained medical professionals in environment specially designed for such procedures. No suggested test or procedure should be carried out unless, in the user's professional judgment, its risk is justified. Whoever applies products, procedures and therapies shown or described in this publication will do this at their own risk. Because of rapid advances in the medical science, IF recommends that independent verification of diagnosis, therapies, drugs, dosages and operation methods should be made before any action is taken.

Although all advertising material which may be inserted into the work is expected to conform to ethical (medical) standards, inclusion in this publication does not constitute a guarantee or endorsement by the publisher regarding quality or value of such product or of the claims made of it by its manufacturer.

### Legal restrictions

This work was produced by IF Publishing, Munich, Germany. All rights reserved by IF Publishing. This publication including all parts thereof, is legally protected by copyright. Any use, exploitation or commercialization outside the narrow limits set forth by copyright legislation and the restrictions on use laid out below, without the publisher's consent, is illegal and liable to prosecution. This applies in particular to photostat reproduction, copying, scanning or duplication of any kind, translation, preparation of microfilms, electronic data processing, and storage such as making this publication available on Intranet or Internet.

Some of the products, names, instruments, treatments, logos, designs, etc. referred to in this publication are also protected by patents and trademarks or by other intellectual property protection laws (eg. «IF», «IIF» and the IF-Logo) are registered trademarks even though specific reference to this fact is not always made in the text.

Therefore, the appearance of a name, instrument, etc. without designation as proprietary is not to be construed as a representation by publisher that it is in the public domain.

Institutions' subscriptions allow to reproduce tables of content or prepare lists of Articles including abstracts for internal circulation within the institutions concerned. Permission of the publisher is required for all other derivative works, including compilations and translations. Permission of the publisher is required to store or use electronically any material contained in this journal, including any article or part of an article. For inquiries contact the publisher at the address indicated.



## Considerations regarding implantological treatment in patients with aggressive periodontal involvement

### Authors

Prof. Dr. Stefan Ihde<sup>1 2</sup>  
Antonina Ihde<sup>1 2</sup>

### Key Words

Bicortical Implants, periodontal disease, immediate functional loading, bone's response to infections, disinfection of the surgical site, Technology of the Strategic Implant®

### How to cite this article

Ihde S., Ihde A.

Considerations regarding implantological treatment in patients with aggressive periodontal involvement

CMF Impl Dir 2021; 15: 202 - 212

---

<sup>1</sup> International Implant Foundation, Evidence and Research Department, 80802 Munich/Germany

<sup>2</sup> Hon. Visiting Professor, Prosthetic Dept. Jaipur Dental College, Maharaj Vinayak Global University, Jaipur, Rajasthan, India

## Abstract

It has been described well that patients with profound periodontal involvement may be treated in a single operation with the Technology of the Strategic Implant®. This group of patients will face no negative effects on the implant treatment stemming from their periodontal disease, if polished Corticobasal® implants are used. Such treatments are completed in an immediate functional loading protocol within a few days<sup>1</sup>, and this time period is sufficient to restore the integrity of the oral mucosa.

## Introduction

Wolfs law<sup>2</sup> explains functional reasons for changes in the morphology and the structure of any bone. This law includes three aspects:

- The organisation of the bone's internal and structure and external morphology according to the principal direction of stress and strain
- The regulation of the necessary bone mass in order to optimize the weight of the bone with respect to its function
- The regulation of the necessary mineralization of bone

But functional stimuli are not the only influences which we can identify and have to consider. In the cranio-facial field we can observe today with the help of computed tomography changes of the bone's morphology and mineralization due to close-by infections. This way we have the

possibility to evaluate the influence of close-by infections on the structure and strength of bone.

Various aspects of this matter are discussed on the example of a case which was treated in an immediate load protocol after removing all teeth and periodontally involved tissues.

## Material and Methods

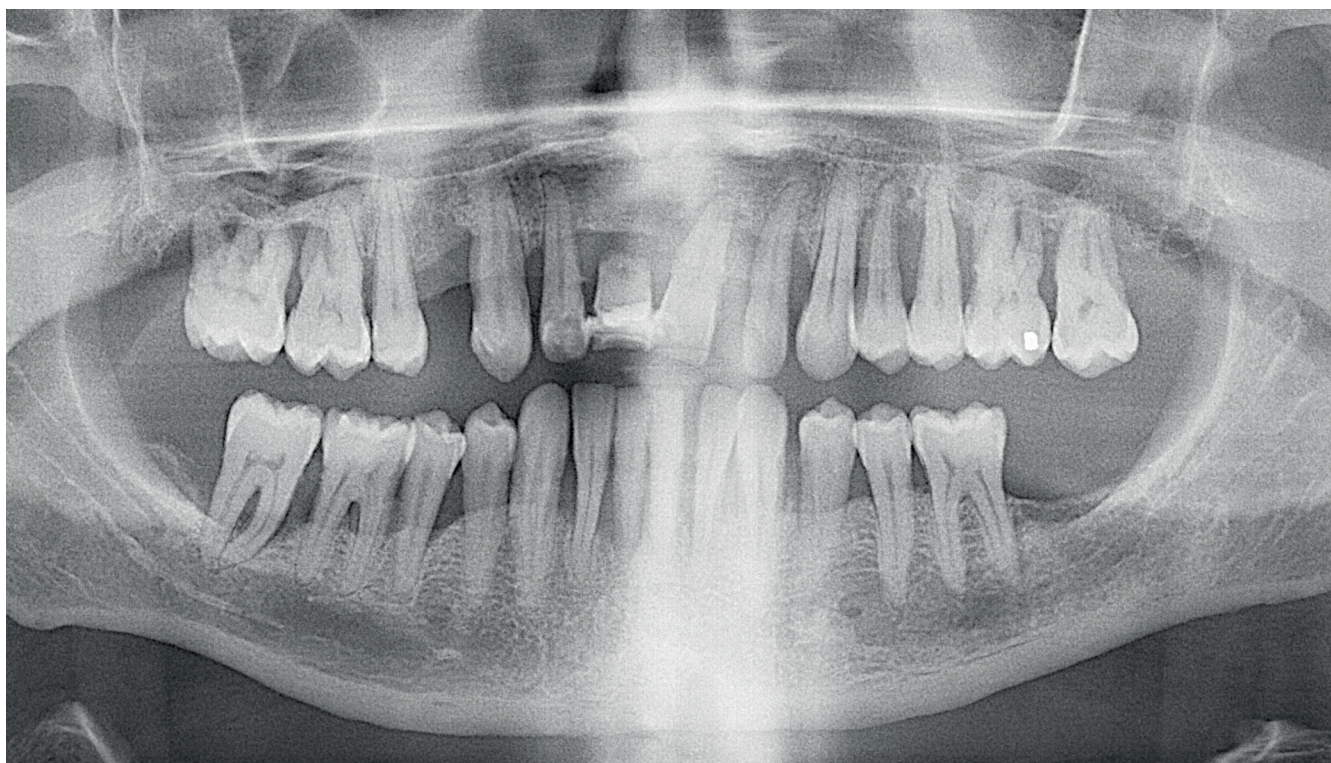
A 50 year old male patient without known systemic diseases, heavy consumer of cigarettes and marihuana requested treatment of his upper and lower jaw after removal of all teeth.

The intervention was done in local anesthesia. After extraction of all teeth the pocket epithelium and the periodontally infected soft tissues were removed completely. This soft tissue removal as done with scalpels, through mechanical cleaning of the bone's surface (e.g. with periosteal elevator or spoons), and with the help of hard-metal cutters on high speed rotating instruments. At the end of this process automatically all papillae were removed. Only healthy mucosa was left on both side of the alveolar crest.

At the end of this debridement the profuse bleeding out of many small vessels in the periodontal tissues stopped quickly. No bleeding out of the bone was found around teeth whose roots were fully surrounded by granulation tissue. All bleeding stemmed from the former desmodontal vessels. Wide gaps were left between the

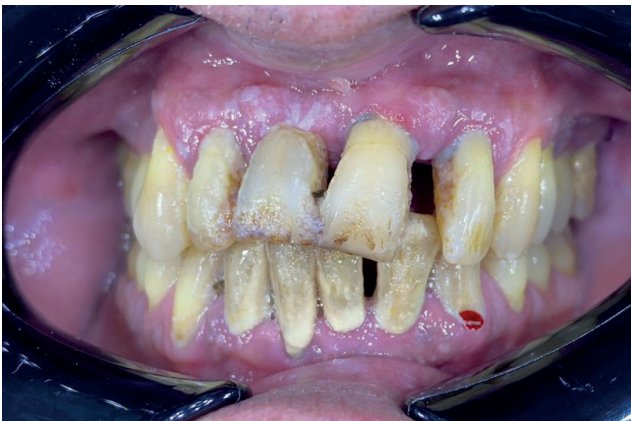palatal and vestibular mucosa. According to conventional protocols of surgery, all gaps are closed tightly at the end of surgery and where it is necessary flaps are raised to allow this. For many years we do not raise flaps any more, we simply approximate and level (relative to the opposite side) the ends of the mucosa as much as possible and we leave the gap for open granulation. This is done while every day 5% Betadine solution is rinsed in all of the oral cavity to virtually eliminate bacteria. This way the healthy mucosa is utilized as much as possible and we leave the open bone gap uncovered for self-healing.

The upper jaw was then treated with 13 polished implants (six TPG<sup>®</sup> uno combination/compression screw implants and seven Corticobasal<sup>®</sup> screw implants), whereas the lower jaw received 10 fully polished implants (two TPG<sup>®</sup> uno combination/compression screw implants and eight Corticobasal<sup>®</sup> screw implants), Fig. 7.

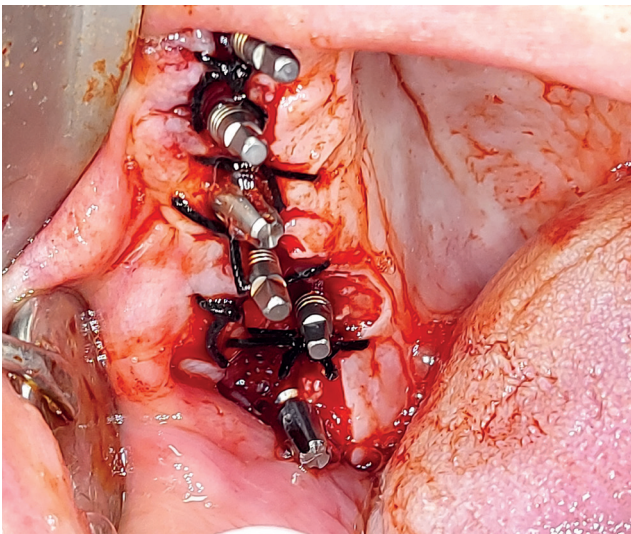


**Fig. 1** The pre-operative panoramic overview picture shows that the in both jaws periodontal destruction has happened and that around most teeth the disease had reached the final stage. Only tooth 36 could have been "saved".

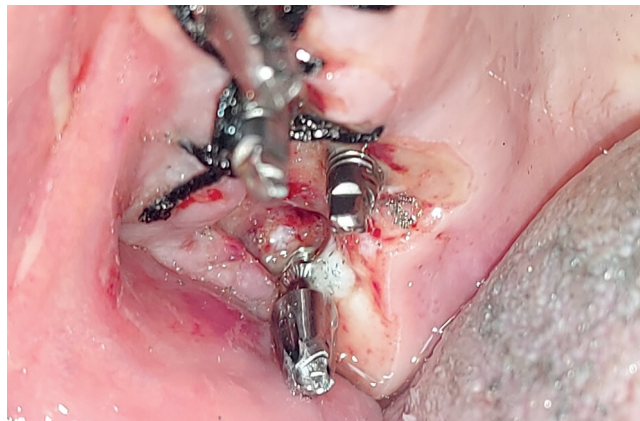



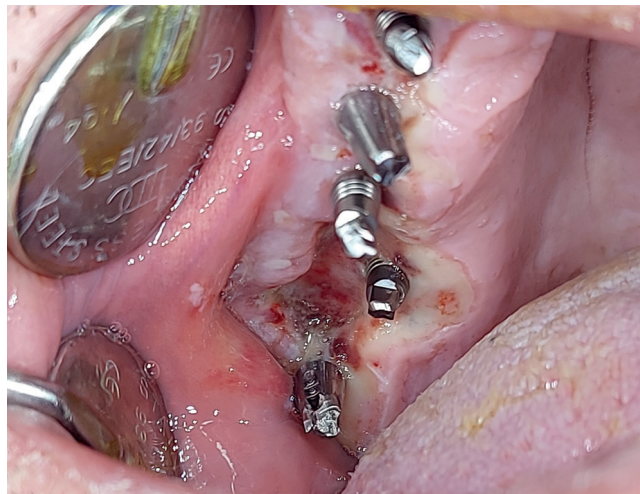**Fig. 2** The pre-operative picture reveals that all teeth are not cleaned at all and that the gums have recessed in many places, but that (compared to Fig. 1) still deep pockets had to be expected.



**Fig. 3** In those areas where not sufficient healthy soft tissues are available, the ends of this tissues are just approximated across the alveolar ridge. In between blood and later the blood clot remains as the only "protection" of the bone. 1.0 or 2.0 silk suture material was used for the closure/approximation of the wounds, because this material allows to pull the ends of the mucosa together with some force, whereas thinner sutures, i.a. 4.0/5.0 filaments would rather cut through the mucosa than to align it. If the ends of the mucosa did not reach the opposite side the sutures were only guiding the end of the mucosa into the desired direction.



**Fig. 4** The same surgical site as shown in Fig.1 appears on the 1<sup>st</sup> postoperative day (18 hours later) as follows: Fibrin is covering the wounds and partly also the exposed bone. At this stage we start to remove the loose sutures, i.e. sutures which do not have a function any more. The surgery sites are thoroughly cleaned with Betadine 5% several times during this appointment. Tooth-try-in was done during this appointment.



**Fig. 5** The patient was left without any temporary on the implants and had received soft/drinkable food. View on the surgery side on the 2<sup>nd</sup> postoperative day, 42 hours postoperatively. The oral cavity was rinsed with Betadine 5% 3 x daily, and the treatment provides used a soft swab to remove carefully any non-attached parts of fibrin. The patient was told not to smoke and he had reduced the consumption of cigarettes per day to "10 only". Bridge try-in was done on this day.

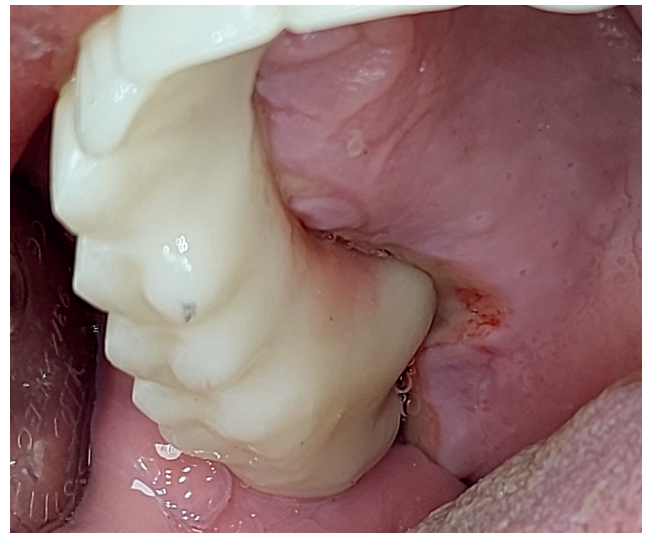
On the 3<sup>rd</sup> postoperative day upper and lower bridges were cemented on the abutments using Fuji Plus (GC Corporation, Japan) hand-mixed cement. The patient received totally 5 x 400 mg Moxifloxacin (1 x per day) as a prophylactic step. Pain was treated with Nimesulid 100 mg powder: The patient consumed two tablets on the day of surgery and 1 tablet each on the 1<sup>st</sup> and 2<sup>nd</sup> post-operative day. He described his pain as minimal and acceptable throughout the whole treatment period.

The wound healing was excellent and we assume that this is owed first of all to the permanent local disinfection with Betadine than to the oral antibiotic treatment.

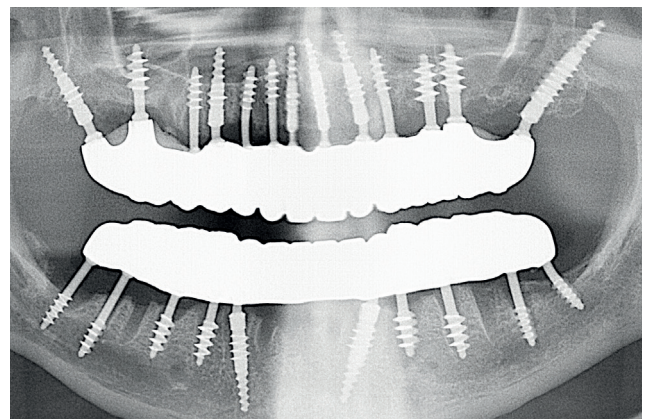
## Results

In the morning of the 3<sup>rd</sup> post-operative day the upper and the lower zirconium bridge were cemented with the help of the permanent cement "Fuji plus". Then the occlusion and masticatory slopes were adjusted. The patient was ordered to come for the first control after three months in order to re-evaluate and to adjust the occlusal and masticatory situation.

Although large areas of the jaw bone were for days without tight (or any) mucosal covering, all wounds and the defects in the mucosa healed uneventfully.



**Fig. 6** On the 3<sup>rd</sup> post-operative day (66 hours post-operatively) both jaws were equipped with cemented circular zirconium bridges. At this stage of healing we observed pink epithelialized zones of the wounds, indicating that all wounds healed uneventfully and speedy after all periodontally involved soft tissues had been removed.



**Fig. 7** Postoperative panoramic view in the upper and lower jaw after also completing the prosthetic treatment: Extraction sockets are well visible, all implants appear to be in sufficient healthy bone to be stable.

## Discussion

### Discussion regarding the procedures of the patient case

Raising a flap could lead to the following disadvantages:

- As a result of flap formation swelling and pain would occur
- Below the flap remnants of infection could get trapped and this again would create pain and it would increase the overall risk of the intervention
- Trapped in infections could descend into the bone due to over-pressure under the closed flaps, as we still have an open bone wound around freshly placed Corticobasal® implants. Over-pressure does not appear in the oral cavity.
- Wherever we raise a flap an even bigger open bone area would be exposed from the periosteum. This will induce later strong re-modelling.
- If mucosa area which provide attached gingiva would be raised from the bone, a considerable part of this flap would lose the "attached-gingiva-properties"
- In smoking patients wound dehiscence is frequent and if it happens all efforts of getting the wounds closed primarily would fail.

The mentioned reasons should convince surgeons to refrain from raising flaps to close extraction derived wounds. In the reality many surgeons do not rely on the self-healing possibilities of the patient nor on the compliance with

order so the patients. They feel that patients are under-treated if wounds are not fully closed.

In the dentist practice a "dry socket" is sometimes observed in the empty socket after the extraction of teeth. Experience with basal and Corticobasal® implants shows, that a "dry socket" never occurs in cases where these implants are placed, even if the wounds are not closed as shown in Figs. 3,4, 5 and 6.

"Periodontal disease" (as per definition) requires the presence of affected teeth in the oral cavity. After the removal of all such teeth, and after removal of the infected soft tissues, the disease has instantly disappeared and no recurrency must be feared. Immediate implant placement was shown to be successful if designs of implants are used, which provide thin and polished mucosal penetration parts<sup>I, III</sup>, whereas the placement of conventional 2-piece implants with rough surface and large diameters have to be used with care and patients have to accept the higher risks which are associated to these implants<sup>IV</sup>.

### Discussion and example of reactions to be expected on/in jaw bones as an response to nearby infections

In order to come to a qualified advice on what to do in profound periodontally involved cases, we suggest to study the reaction of bone to infections in detail.

Bone has a different way to protect itself against



infections compared to soft tissues. In infected soft tissues, the blood supply is increased to the site of infection.

Under regular anatomical conditions the outer layer of each bone is a cortical, and this cortical is surrounded by periosteum, a strong and well perfused membrane. This membrane forms a well-functioning barrier between the zone of high oxygen levels and high blood supply, and the bone's zone of low metabolism. If the periosteum is missing, granulation tissue will replace even cortical bone.

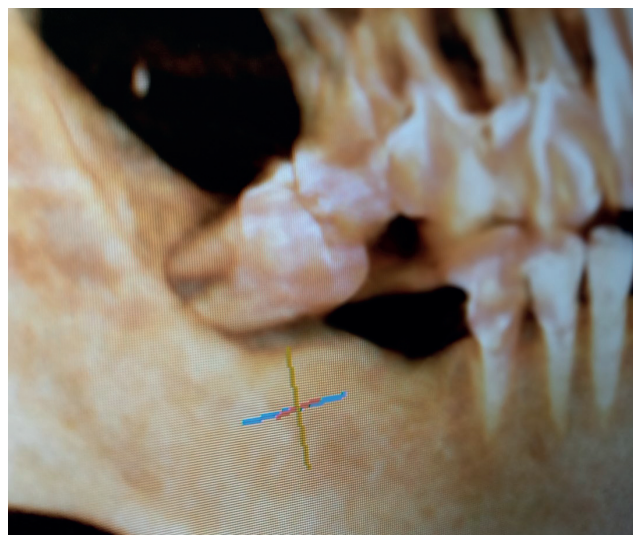
If however, chronic infections are present in the vicinity of bone, the **periosteum may be irritated** in a way that more layers of mineralized tissues will be deposited to enforce/strengthen the existing cortical.

Inside both jaw bones, chronic periodontal disease may lead to a **strongly mineralized barrier zone** within the spongy bone and this barrier zone can be mixed up with the 2<sup>nd</sup> cortical.

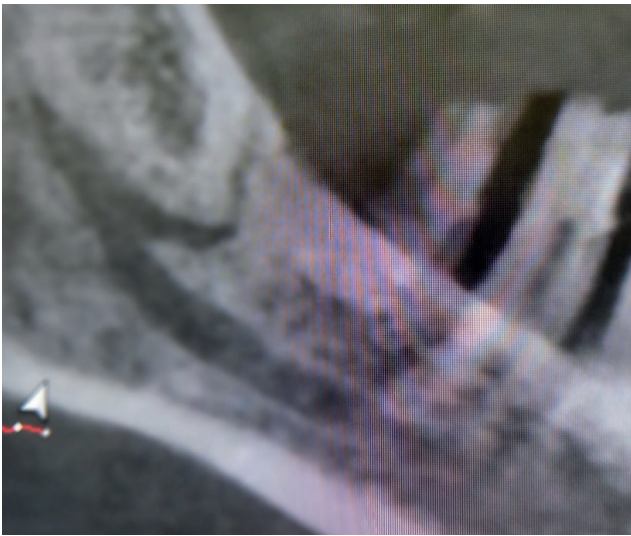This mechanism **of reactive mineralization as an answer to close-by chronic infection** is often overlooked and misinterpreted. In the craniofacial field we can observe these developments easily, while in the long bones such developments occur only under very specific conditions, i.e. in cases of skeletal tuberculosis.

### Example 1

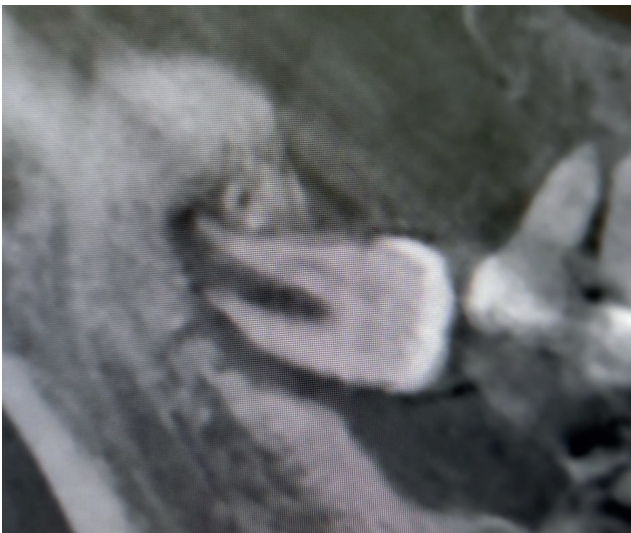
A routine inspection revealed a severely periodontally involved and pathologically migrated-inclined tooth 48. In order to plan the replacement of this and other teeth CBCT was done and it revealed not only that a large amount of granulation tissue surrounding the tooth 48, but also a huge hyper-mineralized zone around distal to it, Fig. 8. Blood supply for the granulation stems from a branch of the inferior alveolar artery, Fig. 9. After the removal of tooth 48 strong arterial bleeding appeared and this bleeding had to be stopped surgically.



**Fig. 8** Tooth 48 is pathologically migrated-inclined and shows on the CBCT3D - reconstruction severe periodontal involvement. It is completely surrounded by granulation tissue. The oral mucosa does not show any signs of infection. Hence, we have to assume that all of the blood supply stems from the branch of the inferior alveolar artery.



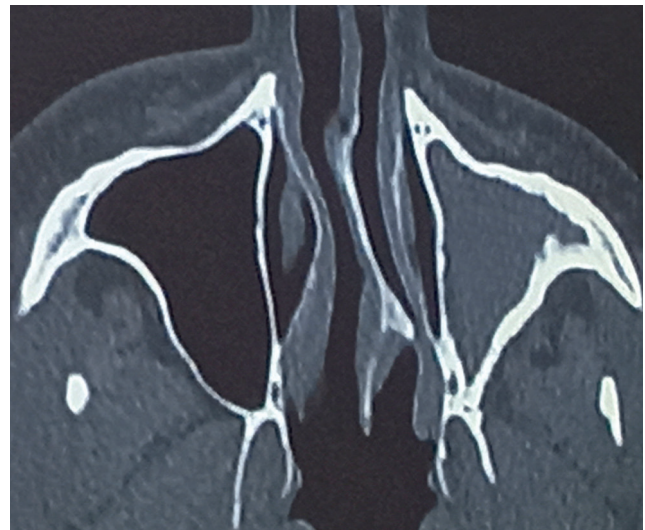
**Fig. 9** The CBCT examination through the center of the mandible reveals that indeed a strong branch of the inferior mandibular artery is supplying the granulation zone around tooth 48 and this vessel penetrates the highly mineralized cortical.



**Fig. 10** The granulation tissue (providing high blood perfusion) which surrounds the tilted 3<sup>rd</sup> molar has led to a strong reactive mineralization distally to the infection site and in the crestal cortical below that tooth. The thickness of these highly mineralized bone areas confirms that this process has been ongoing for a long time.

### Example 2

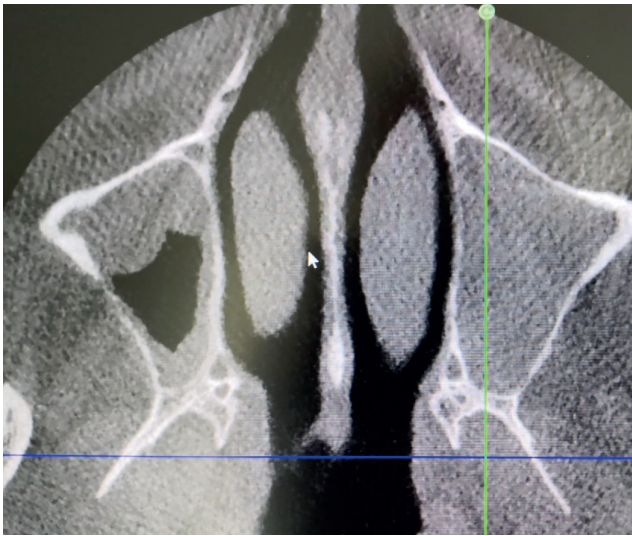
This CT-cross-cut shows a maxillary sinus which had been chronically infected for more than 10 years and it is fully filled with granulation tissue. As an answer to the chronic infection the cortical walls became significantly thicker than the walls on the healthy side, Fig. 11.



**Fig. 11** After more than 10 years of chronic infection the cortical of the maxillary sinus on the infected side (right side of the picture) had increased significantly in its thickness.

### Example 3

A routine-inspection of the maxillary sinuses revealed that on the right side of the picture an acute maxillary sinusitis is present and that the cortical bone nevertheless shows a regular thickness, whereas on the left side of the picture chronic granulation coats quite localized the cortical walls of the maxillary sinus, and there the cortical appear thicker, Fig. 11.



**Fig. 12** The thickness of the cortical of the maxillary sinus is increased in such regions where the cortical is overgrown with granulation tissue (left side of the picture), whereas an acute infection on the right side of the picture does not lead to such result (in a short time).

### Considerations regarding infection in the vicinity of jaw bone

Among dental practitioners the fear of osteomyelitis is traditionally significant, although this condition is quite rare and mostly connected to problems with the teeth<sup>v</sup>. This condition is rarely seen around dental implants as long as they are still apically osseointegrated<sup>vi, vii</sup> and infection could not continue apically because bone reacted to infection with increasing mineralization.

Osteomyelitis is an infection of the bone tissue, it happens inside bone, and bacteria are found inside the Haversian canals. At the same time osteomyelitis appeared in patients with

comorbidities like, for example diabetes<sup>viii</sup>. Various co-factors influence the development and the potential healing of osteomyelitic areas<sup>ix</sup>, and these cofactors must be considered to be risk factors for treatment with Corticobasal<sup>®</sup> implants.

Granulations **inside** the bone appeared replacing the bone tissue as a respond to infection (example: peri-apical granulation). And finally, areas of osteitis have to be distinguished from intra-bony granulations and from areas of osteomyelitis.

The mentioned examples show a “positive” effect of chronic infections of jaw bones. Both the amount and the quality of the bone increases. We can assume (unless other co-factors for the development of infections of or in the bone prevail), that bone in the vicinity of a profound peri-odontal area is well prepared for our interventions.

### Conclusion

If chronic infections exist in the vicinity of (jaw) bone, the bone will increase its amount of mineralization and/or the bone mass, while within soft tissues (which are affected by the same infection) the blood perfusion is increased. The increased perfusion cannot harm the mineralized tissue nor alter its nature after protective increase of mineralization has taken place in the bone.

In bone areas where an aggressive periodontitis has reduced the amount of jaw bone, we can expect thin but well mineralized bone areas that allow stable anchorage of cortical implants. The reactive increase of the cortical's quantity and/or quality allows us also to keep gaps open in the mucosa and wait for spontaneous healing of these defects. Local disinfection of the surgical sites is mandatory, as we cannot expect that oral/i.v. antibiotics will have a considerable effect on the soft tissues and anyway they will penetrate into strongly mineralized tissues or through its system of canals. Even in such harsh conditions as shown in Figs. 1-5 we can provide a predictable treatment by using the Technology of the Strategic Implant®.

Due to the negative effect of rough implant surfaces and large implant diameters, this simplified treatment approach is never possible for conventional 2-stage-implants.



- <sup>i</sup> Pałka Ł, Lazarov A. Immediately loaded bicortical implants inserted in fresh extraction and healed sites in patients with and without a history of periodontal disease. *Ann Maxillofac Surg* 2019;9:371-8.
- <sup>ii</sup> Wolff J (1892): *Das Gesetz der Transformation der Knochen*. Verlag Aug. V Hirschwald, Berlin (in German language)
- <sup>iii</sup> Ihde S. (Edt.), *Principles of BOI*, Springer, Heidelberg 2004
- <sup>iv</sup> E King, R Patel, A Patel, L Addy  
Should implants be considered for patients with periodontal disease?  
*Br Dent J*. 2016 Dec 9;221(11):705-711.
- <sup>v</sup> Andre C., R-H Khonsari, D Ernenwein, P Goudot, B Ruhin  
Osteomyelitis of the jaws: A retrospective series of 40 patients  
*J Stomatol Oral Maxillofac Surg* 2017 Oct;118(5):261-264.
- <sup>vi</sup> Yahalom R, Ghantous Y, Peretz A, Abu-Elnaaj I.  
The Possible Role of Dental Implants in the Etiology and Prognosis of Osteomyelitis: A Retrospective Study.  
*Int J Oral Maxillofac Implants*. 2016 Sep-Oct;31(5):1100-9. doi: 10.11607/jomi.4527.
- <sup>vii</sup> PaulaFridDDSaKnutTornesDDS, PhDbØyunnNielsencNilsSkaugDDS, PhDd  
Primary chronic osteomyelitis of the jaw—a microbial investigation using cultivation and DNA analysis: a pilot study; *Triple-O*, Vol. 107, May 2009, Pages 641-647
- <sup>viii</sup> Marc Baltensperger, Klaus Grätz, Elisabeth Bruder, Richard Lebeda, Miro Makek, Gerold Eyrich  
Is primary chronic osteomyelitis a uniform disease? Proposal of a classification based on a retrospective analysis of patients treated in the past 30 years  
*J Craniomaxillofac Surg* 2004 Feb;32(1):43-50. doi: 10.1016/j.jcms.2003.07.008.
- <sup>ix</sup> Robertsson C, Sävendahl L, Cardemil C.*Bone Rep*. 2021 May 7;14:  
Primary chronic osteomyelitis of the jaw: Rapid improvement after hormonal suppression in a girl with precocious puberty.  
*Bone Rep*. 2021 Jun; 14: 101089.  
Published online 2021 May 7. doi: 10.1016/j.bonr.2021.101089
- <sup>x</sup> Bali RK, Sharma P, Gaba S, Kaur A, Ghanghas P.  
A review of complications of odontogenic infections.  
*Natl J Maxillofac Surg*. 2015 Jul-Dec;6(2):136-43.