

Contents lists available at [ScienceDirect](https://www.sciencedirect.com)

International Journal of Surgery Case Reports

journal homepage: www.casereports.com

Immediate rehabilitation of a rheumatoid arthritis patient with single-piece implants

Vivek Gaur^{a,*}, Narender Singh^b, Anita Gala Doshi^c, Bhathini Chandrahass^d

^a Department of Oro-Maxillofacial Surgeon, Jaipur Dental College, Maharaj Vinayak Global University, Jaipur, India

^b New Delhi, India

^c Department of Prosthodontics, Sankalchand Patel University, Visnagar, Gujrat, India

^d Dr Hedgewar Smruti Rugna Sewa Mandal Dental College and Hospital, Hingoli, India

ARTICLE INFO

Article history:

Received 6 March 2021

Received in revised form 3 April 2021

Accepted 4 April 2021

Available online 7 April 2021

Keywords:

Rheumatoid arthritis

Single piece implant

Immediate loading

Case report

ABSTRACT

INTRODUCTION AND IMPORTANCE: The aim of this article is to report the long-term outcome of full mouth rehabilitation with single piece, smooth surface implants following immediate loading protocol on a patient suffering with RA and severe unilateral condylar resorption.

CASE PRESENTATION: Here, we present a challenging case of a patient suffering from Rheumatoid Arthritis who was stabilized and completed successfully with a 4 year follow-up period. Prosthetic management optimized the inter-occlusal relationship to maintain both function and esthetic integrity. Single piece implants are designed to engage and take support from the cortical bone low in metabolic activities thus promoting the force transmission through apical threads that are engaged in the cortical bone.

DISCUSSION: Rheumatoid Arthritis [RA] is an auto-immune inflammatory condition in which the inflamed and hypertrophic synovial membrane grows into the articulation surfaces. The Temporomandibular Joints [TM] are frequently involved in rheumatoid arthritis. According to the literature on RA, due to frequent periodontitis, decreased salivary secretion, medication, as well as decrease in bone regenerative potential, RA is often considered as a relative contraindication in the use of implants. Atrophic jaws and cases with comorbidities like osteoporosis, diabetes, rheumatoid arthritis, periodontally infected cases are restored with high success by single piece smooth surface.

CONCLUSION: To the best of our knowledge, this may be the first case of immediate functional loading by bi-cortical single piece implants.

© 2021 The Authors. Published by Elsevier Ltd on behalf of IJS Publishing Group Ltd. This is an open access article under the CC BY-NC-ND license (<http://creativecommons.org/licenses/by-nc-nd/4.0/>).

1. Introduction

Rheumatoid Arthritis [RA] is an auto-immune inflammatory condition in which the inflamed and hypertrophic synovial membrane grows into the articulation surfaces. The Temporomandibular Joints [TM] are frequently involved in rheumatoid arthritis. It is more common in females and the incidence increases with age. Usually small joints of the hand, wrist, knees and feet are affected in a bilateral symmetrical fashion and so does the TM joints, which may be bilateral or unilateral. Bilateral destruction of joints may lead to antero-superior positioning of condyles leading to an open bite. During unilateral involvement, the jaw is deflected towards the affected side while opening. There is pain, stiffness, swelling which is worst in the morning and that improves during the day. Clinical findings include sound, pain, stiffness in the joint and limited movement, muscles of mastication mainly

masseter and temporalis are tender on affected side or bilaterally [1]. Furthermore in RA patients, radiographic imaging reveals cortical erosions, subcortical cysts, flattening of the condylar head and articular eminence, classical pencil shaped condyles, subcortical sclerosis, and narrowing of the joint space [1]. Moreover, TM dysfunction, periodontal diseases, salivary gland dysfunction, oral candidosis/angular cheilitis, oral ulceration are more common in RA patients [2]. Furthermore, RA is a systemic, chronic and autoimmune disease that displays an extremely high level of pro-inflammatory cytokines and inflammatory cells that resemble the activity that occurs in periodontal disease and periapical disease. This activity can spark an increased inflammatory response that may lead to further tissue destruction via gamma-delta T cells and create increased oxidative stress.

According to the international literature in RA, due to frequent periodontitis, decreased salivary secretion, medication, as well as decrease in bone regenerative potential, RA is considered as relative contraindication in implantology [3]. Dental implantology has been successfully established as a proven treatment modality for the replacement of lost stomatognathic structures, restoring aesthetics and function, with two piece or single piece fixtures. The history of

* Corresponding author at: 417, K M Trade Tower, Kaushambi, Ghaziabad, Uttar Pradesh, India.

E-mail address: drvivekgaur@yahoo.co.in (V. Gaur).

intraosseous implantology, as a whole, begins with the introduction of the Formigini screw. Single piece smooth surface implants were subsequently derived from titanium bars [4]. It's always challenging in restoration of lost structure and function with patients having associated co-morbidities/metabolic disorders resulting in deficient available bone qualitatively and quantitatively.

The aim of the surgeon is to restore the lost oral structure and function with the least trauma and expenses for the patient as well as to follow the immediate functional loading protocol. The surgeon must apply the technology/technique most suitable available for the restoration of the present case with reasonable long-term prognosis. Single piece implants is a method/technology using single piece implants, which are smooth surface, are osseofixated in cortical bone/buttrass areas with an intention to use them in an immediate loading protocol [5]. There have been sufficient evidences in support of Single piece jaw implants for restoration of osteopenic jaws, immediate extractions situations with or without infected sockets, atrophic jaws, without expensive and painful grafting procedures as are devoid of immediate complications like graft infection/failure and late complications with conventional/alveolar implantology like abutment screw fractures, loosening, peri-implantitis, etc [4,6–11]. Bicortical smooth surface single piece implants have been placed with success in patients with history of periodontitis [12]. The aim of this article is to report the long-term outcome of full mouth rehabilitation with single piece, smooth surface implants following immediate loading protocol on a patient suffering with RA and severe unilateral condylar resorption.

2. Case report

This case report is in accordance with the SCARE 2018 checklist [13]. A 60 years old Asian female patient presented with mobile teeth in the maxilla and mandible experiencing difficulty in chewing in conjunction with the right maxillary fixed prosthesis. A history of osteoporosis, which is common at that age was presented in the medical history. The patient was on homeopathic medicine and was advised to continue. The chief complaint involved head ache and pain during jaw movement and she co-related the pain with the mobile teeth. On examination, there was mild deviation of lower jaw towards the right side. Extra oral examination revealed tenderness in all muscle of mastication, lateral pole of TM joint and retrodiscal tissue. Intra oral examination reveal large discrepancy in joint centric relation (CR) and maximum intercuspation position (MIP). In order to differentiate the origin of pain is from muscle or joint origin, Lucia zig was used where patient report of increased in pain on biting on Lucia zig, which confirm that the pain is from joint. Extra-oral examination revealed prominent chin as with decreased vertical dimension at occlusion, no facial asymmetry was noted. Cone beam tomogram (CBCT) was advised with orthopantomogram (OPG) and routine blood pathology examination. Cone beam CT scan was performed on an Orthophos SL to evaluate the maxilla, mandible and T.M joints bilaterally. Marked flattening of the condylar head with reduction in its overall dimensions and altered morphology noted. Surface irregularities noted on the superior surface of the right condyle. Flattening of the articular eminence and erosion noted along its posterior slope and roof of the glenoid fossa. Reduced joint space noted. "Parrot Beak appearance"/"Pencil shaped appearance" noted with respect to right condyle. Fine wiry radiopacities noted emanating from the articulating surfaces into joint space. Mild flattening and surface irregularities noted at superior and posterior surface of the condylar head of the left side associated with thinning of the roof of the glenoid fossa at left region. Impacted inverted right lower third molar was observed along with cystic lining at right ramus.

2.1. Surgical protocol

After informed consent was obtained, patient was advised first occlusal splint till the occlusion and joint stabilized, but had great difficulty in eating and insisted on receiving a permanent solution. So patient was advised Single piece immediate implants rehabilitation with the hybrid prosthesis as a splint, which would be periodically adjusted till the occlusion and TMJ was stabilized. The procedure was performed by an Oral and Maxillofacial surgeon. A day before surgery tab.Cefakind™ 500 mg [cefuroxime] was prescribed to be taken twice daily for 5 days. Patient was operated on routine dental chair under local infiltration. Septanest® [4% articaine with 1:100,00 epinephrine] was injected, no blocks were made. Immediate extraction and BECES® implants [Simpladent GmbH; Switzerland] were placed following manufacturer instruction with 1:1 reduction Kavo® straight and contra-angle handpiece by W&H physio-dispensor. Maxilla were restored with ten implants with bilateral double pterygoid and anterior nasal cortical engagement was made with four KOC PLUS® [Simpladent GmbH; Switzerland] and two BECES® implants. Lower jaw was equipped with eight BECES® implants, distally engaging lingual cortical beneath the mylohyoid undercut with two implants bilaterally, anterior four BECES® laterally inclined towards midline in the region of high mineralization present between mental foramen. Implants were placed at strategic locations according to supporting polygon concept [14]. A maximum polygon was formed in the sagittal and transversal directions and reduces leverages and flexural movements to a minimum by sufficiently equipping the jaws [9,15–17]. Alvelectomy was performed, maxillary and mandibular ridge was made flat in order to achieve the desirable prosthetic outcome with minimal post-operative shrinkage. Cyst enucleation with removal of lower right 3rd molar was done, and sutured with Ethicon® 5003, 3-0 silk sutures. Implants abutment were aligned prosthetically by bending with IT2 BECES® tool. Copious Betadine® 5% [Povidone-iodine] irrigation was used as an antiseptic. Post-operatively, tab.mefanic acid was prescribed thrice daily for 5 days as an analgesic.

2.2. Prosthetic protocol

Impression was made immediately after surgery with prosthetic transfers and close tray impression technique. Stock metal impression tray was loaded with silicon putty Flexceed® [Fuji, GC], jaw relationship was established with Aluwax® [Aluminium reinforced wax] by Bio-Art® facebow semi-adjustable articulator. Second day of the surgery metal framework trial made on implants; final vertical dimension is recorded by Aluwax®. Teeth alignment checked with lip support and phonetics, and in evening semi-permanent metal to PMMA hybrid prosthesis is cemented over implants by resin based permanent glass ionomer Fuji plus® [GC] cement. Prosthesis is made sanitary at posterior region and anterior modified ridge lap in both jaws for aesthetics and self-cleanliness. Lingualized occlusal scheme is followed on circular/horse-shoe prosthesis without any contacts between the anterior canine to canine keeping the centric relation equal to the centric occlusion [18] in order to support the joint in all excursive movement. Because of active inflammatory joint disease, occlusion was not stable, hence a hybrid prosthesis was preferred instead of a metal ceramic. This could act as a stabilization splint with progressive adjustment of the occlusion as the condyle's position tends to change during its adaptive remodeling.

Intensive follow-up and adjustment in occlusion were done until a stable TMJ was achieved. After the joint stabilized to a point that required only minimal occlusal adjustment, the mandibular hybrid prosthesis was changed to metal ceramic. Counselling sessions were followed up with the patient. We also explained that the

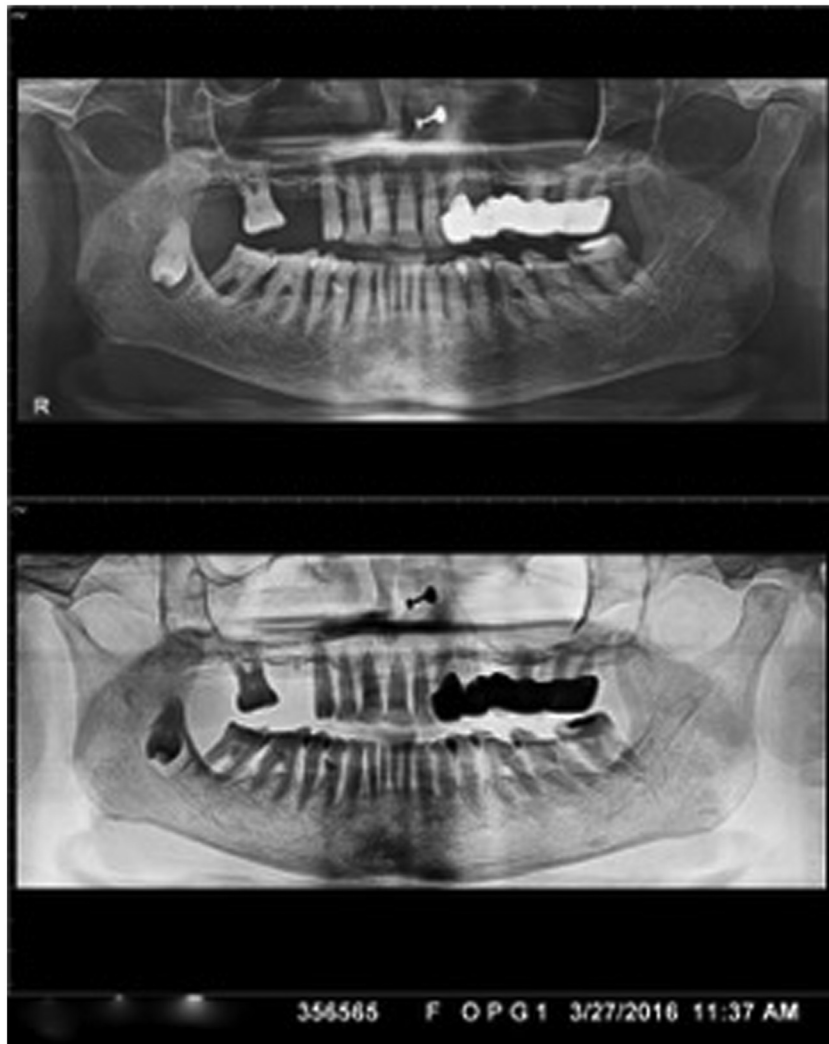


Fig. 1. Pre-operative orthopantomogram.

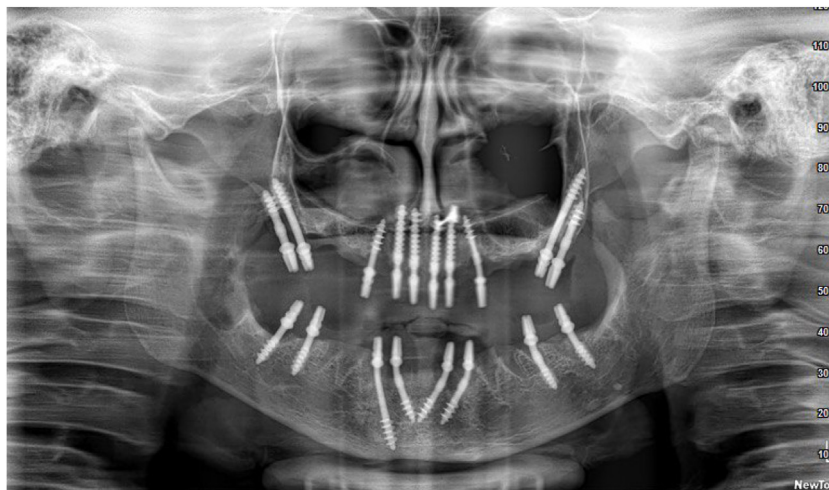


Fig. 2. Immediate post-operative orthopantomogram march 2016.

best results achieved would not completely stop all degeneration at the articular surfaces, but it could usually be slowed to a level that allowed occlusal-muscle harmony to be maintained with minimal periodic occlusal adjustment. The result was a satisfied patient chewing comfortable with nearly 4 years of function with no report

of any complaints. One BECES® implant at right upper canine was removed as it got damaged while changing the prosthesis second time. Stable bone level without any radiolucency around implants, nor infection was observed in the follow-up radiographs. [Figs. 1–7](#) depicting the implant placement with follow-ups.

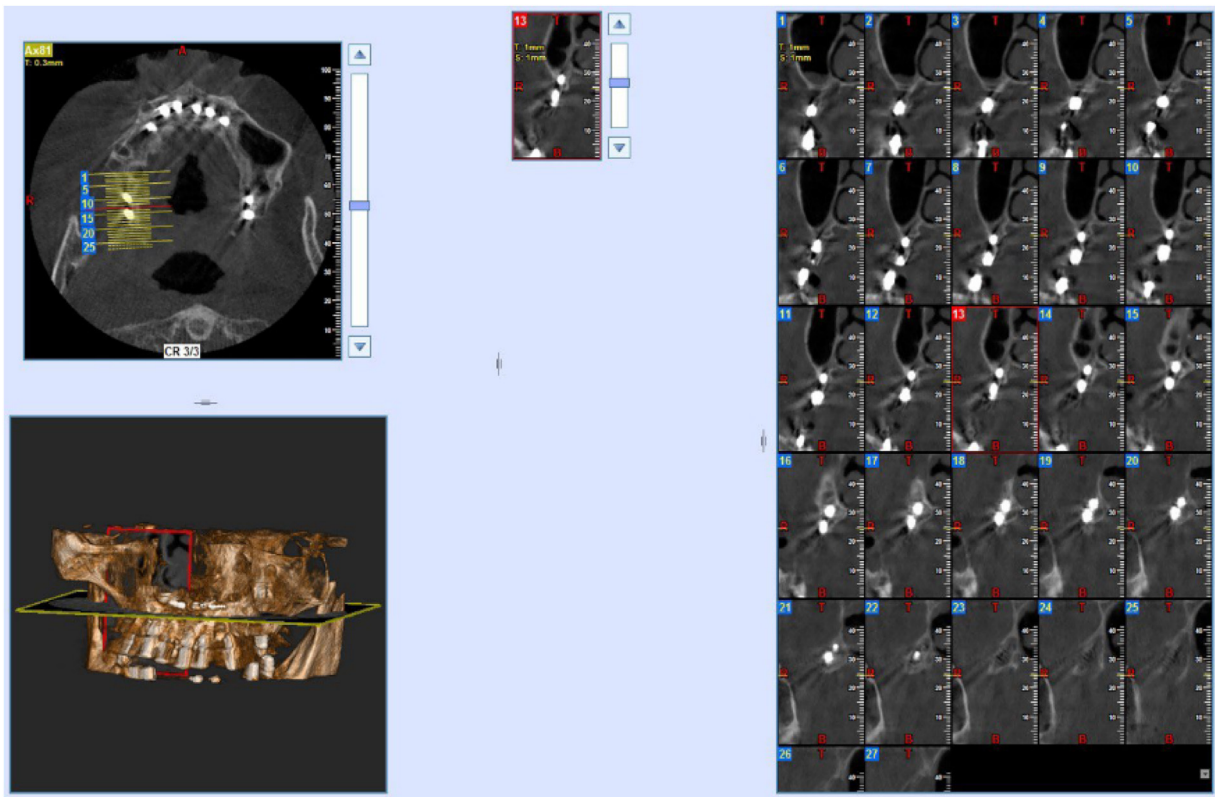


Fig. 3. Right double pterygoid implants placement.

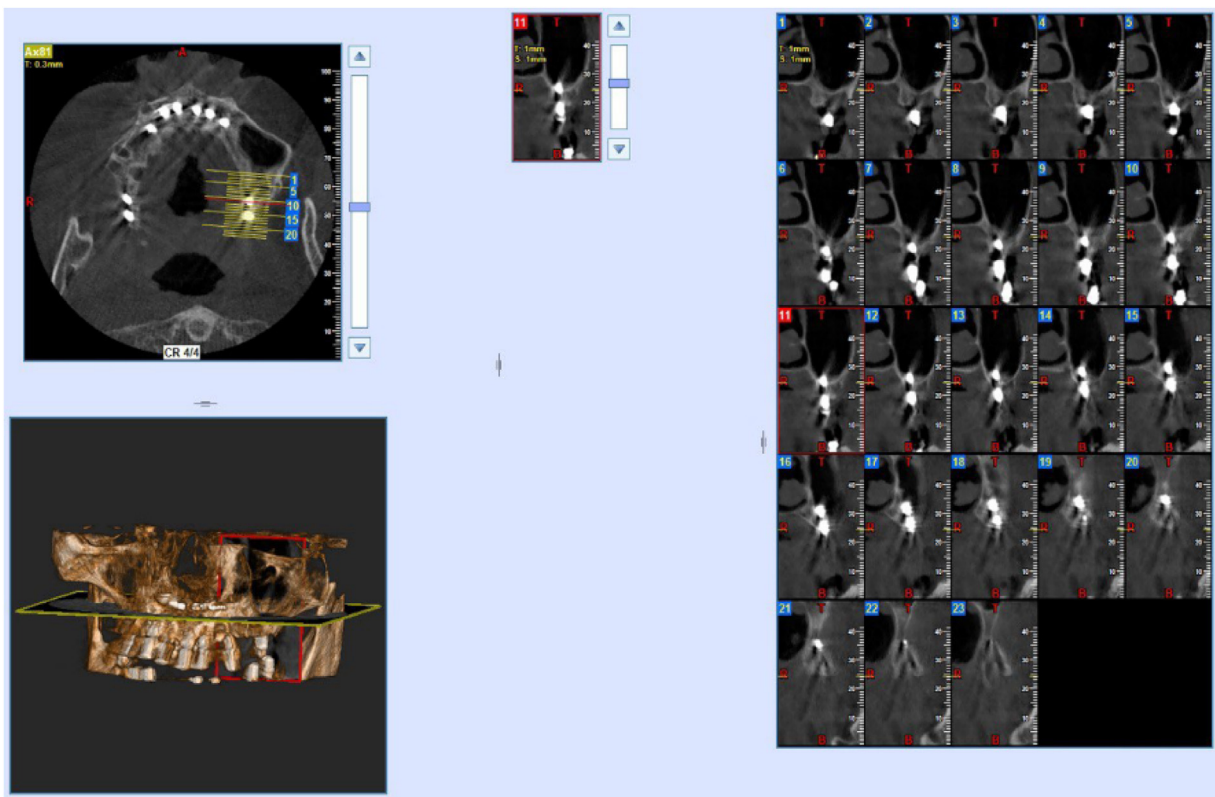


Fig. 4. Left double pterygoid implants placement.

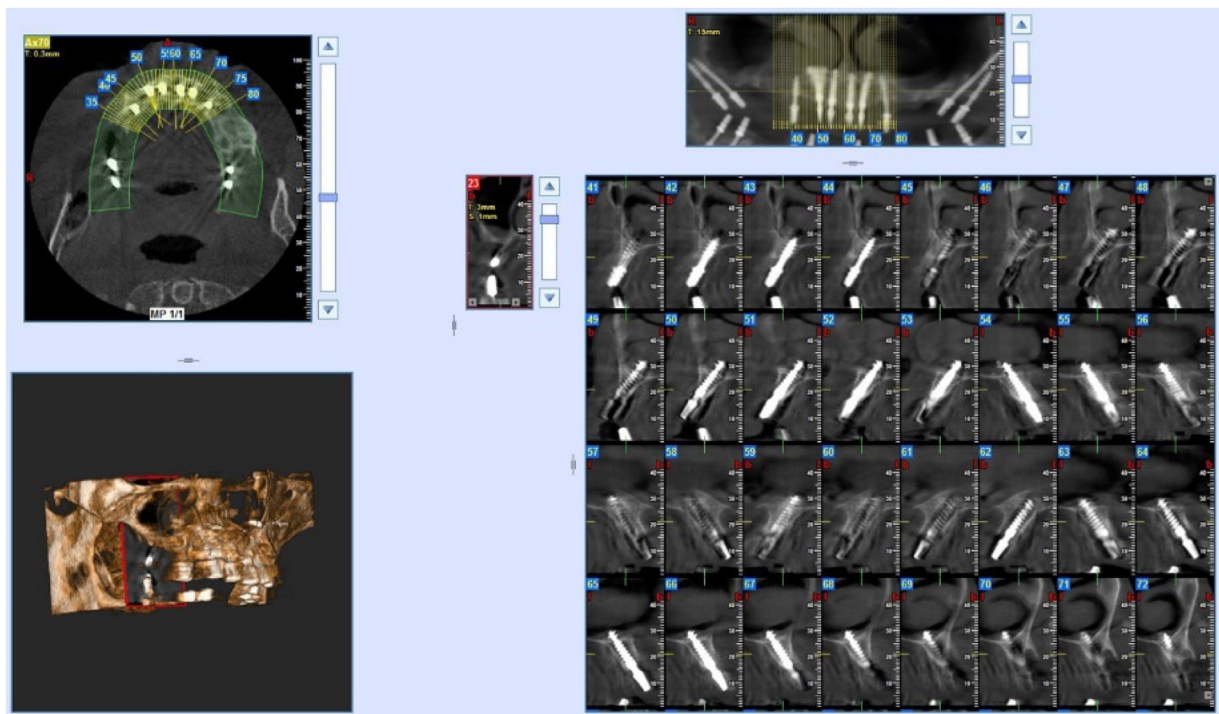


Fig. 5. Nasal cortical engagement.

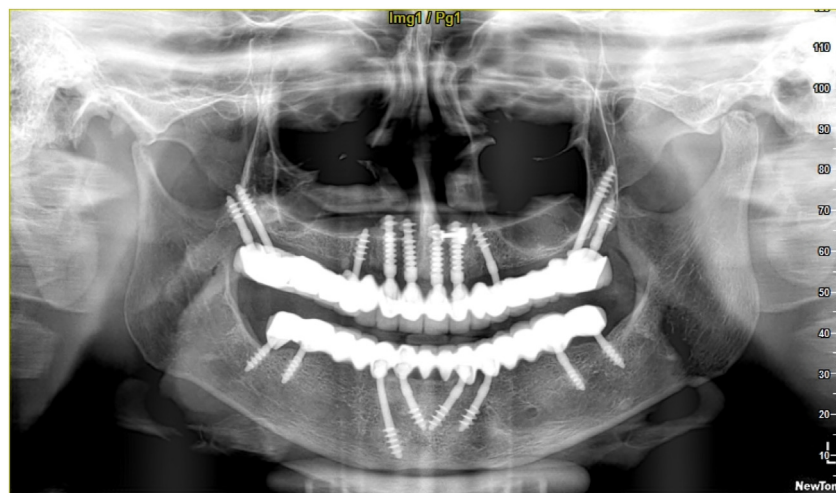


Fig. 6. June 2018 follow-up orthopantomogram.

3. Discussion

RA patients often present with comorbidities which add to the complexity of clinical management. Orofacial conditions associated with RA include periodontal disease, TM dysfunction and salivary gland dysfunction. RA represents a chronic inflammatory disease leading to arthritis, bursitis and tendovaginitis as a result of synovitis eventually leading to joint destruction [19]. RA is frequently accompanied by osteoporosis as a result of increased systemic bone turn over and anti-inflammatory and/or combined anti-immune treatment regimen. Patients suffering from osteoporosis do not possess the optimum bone condition necessary for placement of dental implants and establishment of osseointegration, which are critical factors for the success of dental implant treatment [20]. Incidence of periodontal disease with RA is twice as much [21], they both are chronic inflammatory diseases. Both conditions fea-

ture excessive destruction of collagen-rich tissues: in RA there are bone, cartilage and other periarticular tissues; in periodontal disease there are alveolar bone, periodontal ligament and gingiva [22]. In the literature, there are many studies and systematic reviews with meta-analysis showing strong evidence that history of periodontitis is a risk factor for such complications as implant loss, peri-implantitis, and implant-bone loss [23] (Fig. 8).

This case is unique because immediate functional loading is quite challenging on patients with history of osteopenia, osteoporosis, rheumatoid arthritis, periodontal disease, diabetes, etc. Single piece smooth surface Single piece implants are the treatment of choice for restoration of healthy and compromised situations. There seems to be sufficient evidences emerging to support a one-stage non-submerged protocol which can achieve success rate comparable to implants placed in a two-stage submerged protocol [23]. But there are sufficient scientific articles describing polished

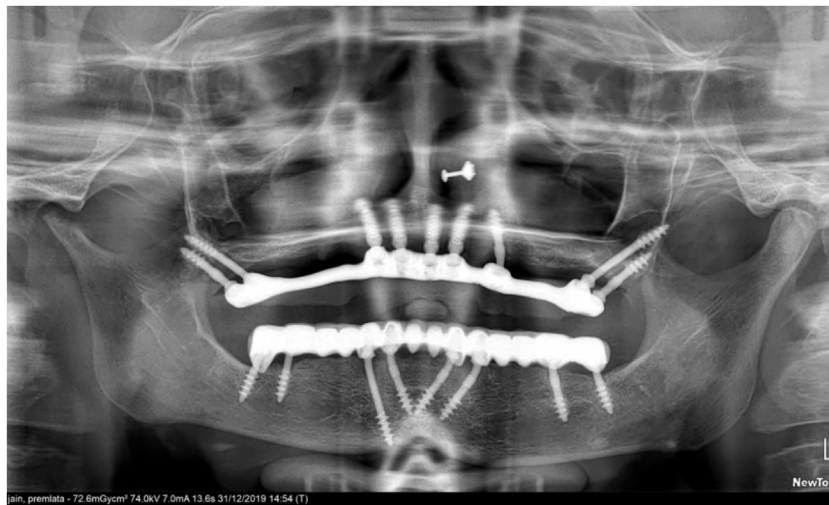


Fig. 7. December 2019 follow-up orthopantomogram.

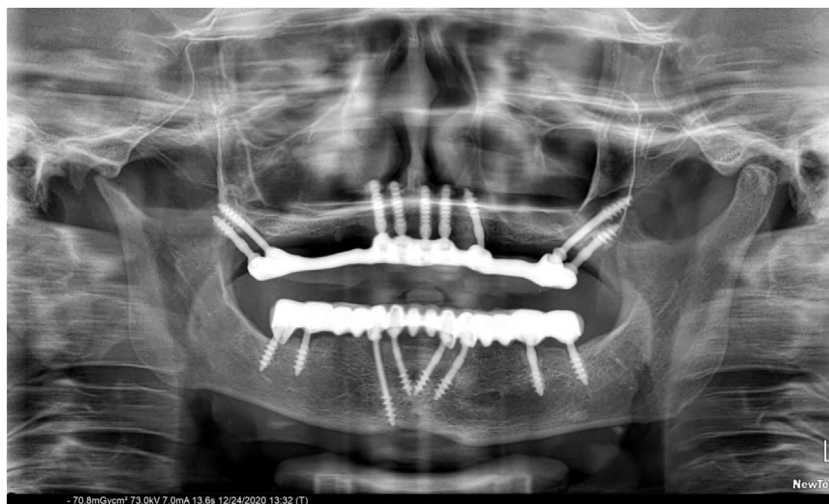

Fig. 8. December 2020 follow-up orthopantomogram.

surface single piece implants in periodontally involved cases with success [13]. Bicortical screw implants like Single piece implants provide bendability in the neck area and have polished surface and the thin neck which, according to Berglundh et al., might be reason for lower progression rate of peri-implantitis [24]. Furthermore, in two-piece rough surface/surface treated implants, the abutment-implant connection, inherit surface roughness $Ra > 2\mu m$, bone level connection, high surface energy and wettability makes unsuitable to treat the cases with history or higher prevalence of periodontitis leading to peri-implantitis [25–27]. Single piece implant supported prosthesis have a positive impact on oral health and highly increases patient satisfaction [28,29] with the advantages of smooth surface and a bendable body and no incidences of peri-implantitis, Single piece implants may also be termed as Oncology Implant [30].

4. Conclusion

Atrophic jaws and cases with comorbidities like osteoporosis, diabetes, rheumatoid arthritis, periodontally infected cases are restored with success by single piece smooth surface Single piece implants. They are designed to engage and take support from the

cortical bone low of metabolic activities like cortical and buttress and force transmission through apical threads engaged in cortical, keeping crestal cortical least affected are the implant of choice. The success entirely depends upon the operator knowledge of occlusion and right surgical technique. Delayed complications like abutment screw fracture/loosening, peri-implantitis, grafting failure is avoided successfully. A challenging case of patient suffering from Rheumatoid Arthritis was stabilized and completed with success having close to 4 years follow-up. Prosthetic management optimized the inter-occlusal relationship to maintain both function and esthetic integrity. This was made possible by reducing the mechanical loads, keeping soft loading with metal to acrylic hybrid prosthesis and using as stabilization splint, obtaining a proper occlusal relationship and keeping the most terminal part of chewing surfaces out of occlusion, keeping lower jaw movements free by removal of interference in protrusive and lateral movements. With the limited knowledge of the author this may be the first case of immediate functional loading by bicortical single piece implants.

Declaration of Competing Interest

No conflict of interest.

Sources of funding

No funding taken.

Ethical approval

Not applicable.

Consent

Not applicable.

Author's contribution

Dr. Vivek Gaur contributed to the cocetualization, validation, managing the patient, writing the manuscript.

Dr. Narendra Singh contributed to the cocetualization, validation, editing and finalization of manuscript.

Dr. Anita Gala Doshi contributed to the cocetualization, validation, editing and finalization of manuscript.

Dr. Bathini Chandrahas contributed to the cocetualization, validation, editing and finalization of manuscript.

Registration of research studies

Not applicable.

Guarantor

Dr. Vivek Gaur.

Provenance and peer review

Not commissioned, externally peer-reviewed.

References

- [1] Ali Balik, Özlem Ocak-Çymendur, Meltem Özdemir-Karataş, Mahmut Ömer, Cökçen-Röhlýg, Bilge Prosthodontic treatment of a patient with rheumatoid arthritis with severe condylar resorption: 4-year follow-up, *J. Istanbul Univ. Fac. Dent.* 48 (2014) 67, 10.17096.
- [2] S. De Souza, R. Bansal, J. Galloway, Managing patients with rheumatoid arthritis, *BDJ Team* 4 (2017) 17064.
- [3] R. Nagy, K. Szabo, A. Szucs, T. Ruszin, A. Joob-Fancsaly, Impact of rheumatoid arthritis in oral surgery and implantology treatment based on literature, *Fogorv. Sz.* 110 (1) (2017) 3–6.
- [4] A.T. Morgano, Functional load in oblique bicortical implants: Parasinusl implants and palatine implants, *J. Oral Implantol.* 39 (2013) 467–474.
- [5] S. Ihde, Indications and treatment modalities with corticobasal jaw implants, *Ann. Maxillofac. Surg.* 9 (2019) 379–386.
- [6] Ag Ahmad, M. Osman, F. Awadalkreem, Full-mouth rehabilitation of a patient with cleidocranial dysplasia using immediately loaded basal implant-supported fixed prostheses: a case report, *Int. J. Surg. Case Rep.* 65 (2019) 344–348.
- [7] S. Ihde, S. Kopp, T. Maier, Comparison of implant survival with implants placed in acceptable and compromised bone: a literature review, *J. Maxillofac. Oral Surg.* 8 (2009) 1–7.
- [8] S. Ihde, A. Ihde, Immediate Loading Guideline to Successful Implantology, International Implant Foundation Publishing, Munich, Germany, 2010.
- [9] S. Ihde, Principles of BOI: Clinical, Scientific, and Practical Guidelines to 4-D Dental Implantology, 1st ed., Springer Science and Business Media, Berlin, Germany, 2005.
- [10] P. Ghalaut, H. Shekhawat, B. Meena, Full-mouth rehabilitation with immediate loading basal implants: a case report, *J. Maxillofac. Surg.* 10 (2019) 91–94.
- [11] S. Ihde, Restoration of the atrophied mandible using basal osseointegrated implants and fixed prosthetic superstructures, *Implant Dent.* 10 (2001) 41–45.
- [12] Ł.R. Pałka, A. Lazarov, Immediately loaded bicortical implants inserted in fresh extraction and healed sites in patients with and without a history of periodontal disease, *Ann. Maxillofac. Surg.* 9 (2019) 371–378.
- [13] R.A. Agha, T. Franchi, C. Sohrabi, G. Mathew, for the SCARE Group, The SCARE 2020 guideline: updating consensus Surgical Case Report (SCARE) guidelines, *Int. J. Surg.* 84 (2020) 226–230.
- [14] S. Ihde, I.A. Cookbook Mastication, 4th ed., International Implant Foundation Publishing, 2020, ISBN 978-3-945889-25-2.
- [15] S. Kopp, J. Kuzelka, T. Goldmann, L. Himmlova, S. Ihde, Modeling of load transmission and distribution of deformation energy before and after healing of basal dental implants in the human mandible, *Biomed. Tech. (Berl)* 56 (2011) 53–58.
- [16] Ihde, et al., New systematic terminology of cortical bone areas for osseo-fixated implants in strategic oral implantology, *J. J. Anatomy* 1 (2) (2016) 007.
- [17] International Implant Foundation: Konsensus on 16 Methods for the placement of Basal Implants: <http://implantfoundation.org/en/consensus-16-approved-methods-2018-menu-en>.
- [18] Rupali Kamath, Lingualized occlusion: an emerging treatment paradigm for complete denture therapy: a review article, *J. Med. Dent. Sci. Res.* 2 (3) (2015).
- [19] G. Krennmaier, R. Seemann, E. Piehslinger, Dental implants in patients with rheumatoid arthritis: clinical outcome and peri-implant findings, *J. Clin. Periodontol.* 37 (10) (2010) 928–936, <http://dx.doi.org/10.1111/j.1600-051X.2010.01606.x>.
- [20] J.C. Keller, M. Stewart, M. Roehm, G.B. Schneider, Osteoporosis- like bone conditions affect osseointegration of implants, *Int. J. Oral Maxillofac. Implants* 19 (2004) 687–694.
- [21] Joanna Koziel, Piotr Mydel, Jan Potempa, The link between periodontal disease and rheumatoid arthritis: an updated review, *Curr. Rheumatol. Rep.* 16 (2014) 408, <http://dx.doi.org/10.1007/s11926-014-0408-9>.
- [22] J.B. Payne, L.M. Golub, G.M. Thiele, T.R. Mikuls, The link between periodontitis and rheumatoid arthritis: a periodontist's perspective, *Curr. Oral Health Rep.* 2 (2015) 20–29.
- [23] Linish Vidyasagar, Peteris Apse, Biological response to dental implant loading/overloading. Implant overloading: empiricism or science, *Stomatologija* 5 (2003).
- [24] T. Berglundh, K. Gotfredsen, N.U. Zitzmann, N.P. Lang, J. Lindhe, Spontaneous progression of ligature induced peri-implantitis at implants with different surface roughness: an experimental study in dogs, *Clin. Oral Implants Res.* 18 (2007) 655–661.
- [25] A. Marrone, J. Lasserre, P. Bercy, M.C. Brex, Prevalence and risk factors for peri-implant disease in Belgian adults, *Clin. Oral Impl. Res.* (2012) 1–7.
- [26] N. Saulacic, B. Schaller, Prevalence of peri-implantitis in implants with turned and rough surfaces: a systematic review, *J. Oral Maxillofac. Res.* 10 (1) (2019) e1.
- [27] W. Teughels, N. Van Assche, I. Sliepen, M. Quirynen, Effect of material characteristics and/or surface topography on biofilm development, *Clin. Oral Imp. Res* 17 (Suppl. 2) (2006) 68–81.
- [28] Fadia Awadalkreem, et al., The influence of immediately loaded basal implant treatment on patient satisfaction, *Int. J. Dent.* 2020 (2020) 10.
- [29] A. Chakranarayan, P. Soni, A. Kapri, R. Kumar, Effectiveness of strategic corticobasal implants in the management of edentulism, *IP Ann. Prosthodont. Restor. Dent.* 6 (2) (2020) 77–86.
- [30] V. Gaur, et al., Mandibular reconstruction using single piece zygomatic implant in conjunction with a reinforcing Fibular Graft Union: a case report, *Int. J. Surg. Case Rep.* 73 (2020) 347–354, <http://dx.doi.org/10.1016/j.ijscr.2020.07.047>, Epub 2020 July 23.

Open Access

This article is published Open Access at [sciencedirect.com](https://www.sciencedirect.com). It is distributed under the [IJSCR Supplemental terms and conditions](#), which permits unrestricted non commercial use, distribution, and reproduction in any medium, provided the original authors and source are credited.