


Volume 13 / Issue 1 / January-April 2022

National Journal of Maxillofacial Surgery

Official Publication of Maxillofacial Society of India

www.njms.in



Zygomatic approach with single-piece implants: A technical note

ABSTRACT

Single piece zygomatic implant, or a remote anchorage implant, is an effective tool for the rehabilitation of the atrophic/resected jaws with least postoperative complications such as screw loosening, screw fractures, bone loss, mucositis, and peri implantitis. The aim of this paper was to summarize a technique for the use of a zygomatic approach for single piece implants. We used the key-words ‘single piece implants’ and the search revealed 700 papers in the PubMed database. After screening through the abstracts, we selected 50 articles that we finally reviewed. Zygomatic fixtures avoid the grafting procedures and cantilever situation, restoration of atrophic or postablative jaws are completed with immediate loading. It is advisable placement of zygomatic implant flapless with surgical guide, but the author believes more on the tactile perception and when the splint is at mucosal or bone level, a small change in orientation will lead the dramatic error in desired angulation leading to unwanted complication.

Keywords: Review, single piece implant, zygomatic implant

INTRODUCTION

Dental implants are nowadays an established treatment modality for the functional rehabilitation of lost stomatognathic structure. Historical evidence dated back of 600 AD for the replacement of incisor with ivory by the Egyptians. With age and losing functional units like tooth which may also due to trauma postablative situation, unrestorable caries and diseases such as periodontitis, atrophy results of the jaws, both upper and lower. The classification of edentulous jaws proposed by Cawood and Howell^[1] concluded in general, changes of shape of the alveolar bone follow a predictable pattern. Alveolar bone changes the shape of the anterior and posterior maxilla and mandible significantly in both the horizontal and vertical axis. Maxillary rehabilitation is always challenging as of deficient alveolar bone both qualitatively and quantitatively which makes the long-term prognosis of the fixture questionable; Schnitman *et al.*^[2] demonstrated that the posterior maxilla was the least successful area for osseointegration with merely a 72% success rate. Augmentation procedures such as onlay grafting, inlay grafting for maxillary antrum and

nasal floor, Le Forte 1 osteotomy with interpositional grafting, and distraction osteogenesis are some of the methods to reconstruct atrophic jaws before implant placement for the implant-supported rehabilitation.^[3-12] Widmark *et al.*^[13] found out that maxillary implants placed in the native bone had a greater success rate than implants placed into grafted bone. Other than the alveolar bone which houses the teeth along with periodontal apparatus and is prone for resorption, both upper and lower jaws lined by corticals and buttress; horizontal, transverse and vertical; that form protective frame around the different craniofacial

VIVEK GAUR, ANITA GALA DOSHI¹, LUKASZ PALKA²

Department of Oral Surgery, Jaipur Dental College, Maharaj Vinayak Global University, Jaipur, Rajasthan, ¹Department of Oral Surgery, Sankalchand Patel University, Visnagar, Gujarat, India, ²Reg Med Clinic, Zary, Poland

Address for correspondence: Dr. Vivek Gaur, 417, K M Trade Tower, Kaushambi, Ghaziabad, Uttar Pradesh, India.
E-mail: drvivekgaur@yahoo.co.in

Received: 10 December 2020, **Revised:** 19 February 2021, **Accepted:** 21 February 2021, **Published:** 20 April 2022

Access this article online	
Website: www.njms.in	Quick Response Code 
DOI: 10.4103/njms.NJMS_274_20	

This is an open access journal, and articles are distributed under the terms of the Creative Commons Attribution-NonCommercial-ShareAlike 4.0 License, which allows others to remix, tweak, and build upon the work non-commercially, as long as appropriate credit is given and the new creations are licensed under the identical terms.

For reprints contact: WKHLRPMedknow_reprints@wolterskluwer.com

How to cite this article: Gaur V, Doshi AG, Palka L. Zygomatic approach with single-piece implants: A technical note. Natl J Maxillofac Surg 2022;13:153-61.

cavities, which are mineralized as of functional reparative osteogenesis owing to facial muscular attachments, being resistant to resorption.^[14] The upper jaw consists of series of frontomaxillary and frontozygomatic as anterior buttress and pterygomaxillary as posterior buttress ideal for the implant anchorage.^[15]

Any ideal treatment modality aimed for the patient should be least traumatic, preferably flapless, less time-consuming, most economical without any comorbidities, and painful procedure such as grafting avoiding immediate and delayed complications postoperatively. Implant surgeons aim for immediate functional rehabilitation whenever possible, fixtures are placed with the support of highly mineralized cortical and buttress and avoiding grafting procedures. The history of intraosseous implantology begins with the introduction of the Formigini screw. Single-piece implants were subsequently derived from the titanium bars. The intrinsic function of the emerging stump was immediate loading. The great stability of the implant in the bone thus demanded was eventually achieved by means of the self-tapping screw and bicortical support.^[16] There has been a switch from sunken two-stage to single-stage implants in view of the usefulness of immediate loading.^[17] Corticobasal implants are single-piece smooth surface implants which are osseofixated in cortical bone/buttress with the intention to use them in an immediate loading protocol.^[18]

Zygoma implants were first introduced in 1998 by Per Ingvar Branemark widely acknowledged as the “Father of Dental Implantology.”^[19] After Branemark, Malevez *et al.* described zygomatic implants as self-tapping screws in commercially pure titanium with a well-defined machined surface available in length 30–52.5 mm and a unique 45° angulated head to compensate for the angulation between maxilla and zygoma.^[20] Original technique was the two-stage delayed loading protocol, Chow *et al.*,^[21] Bedrossian *et al.*,^[22] and Migliorança *et al.*^[23] presented the favorable results and conclusions regarding the immediate loading of zygomatic implants.

A single-piece zygomatic implant is a smooth surface Toulouse lag screw-like fixture with different length available in the range from 35 to 55 mm length, having core diameter of 2.2 mm and apical thread diameter of 4.6 mm for primary anchorage with zygomatic bone, approached through palatal/crestal aspect of resorbed maxilla, having bendable zone to compensate for angulation variation between the maxilla and zygoma and achieving desired position of the abutment prosthetically. ZDI® implant (Simpladent GMBH, Ihde dental, Switzerland) is among the family of corticobasal implants.

Advantage and indication for single-piece zygomatic implants:

1. Prosthetic rehabilitation of atrophic maxilla, fixed or removable
2. Rehabilitation of postresection cases or congenital diseases for fixed or removable obturators
3. Anchorage for extraoral episthesis
4. Avoiding cantilever situation
5. Achieving staggered installation of implant restoration resisting offset loading
6. As a rescue implant
7. Immediate loading and graftless protocol
8. Relatively economical
9. Minimal Armamentarium
10. Unfavorable sagittal relationship of the maxilla to mandible
11. Avoidance of delayed complication such as abutment screw fracture, loosening, and peri-implantitis.

The disadvantage and contraindications for single-piece zygomatic implants:

1. Acute sinus infection and pathology, uncontrolled systemic disease
2. Limited mouth opening
3. Active intravascular bisphosphonate therapy
4. Active or recent therapeutic radiotherapy, chemotherapy, and blood dyscrasias that directly affects bone metabolism
5. Technique demanding, surgeon need to be fairly experienced
6. Always to be used along with anterior or posterior implants been splinted, Quad zygoma is always option when inability to achieve supporting implants, anterior or posterior in condition such as postresection surgery.

The author presents the technique of zygomatic engagement with single-piece implants having emphasis on unique flapless approach following the concept of *Primum non nocere* or “First, do no harm,” and the related surgical anatomical consideration. The Ethical clearance obtained from Maharaja Vinayak Global University, Jaipur with reference no. MVGU/ADM/2020/437 and dated 24/09/2020.

Applied anatomy

The zygomatic bones are a pair diamond-shaped, irregularly-shaped bones that protrude laterally and forms the prominence of the cheeks, a portion of the lateral wall, the orbit floor, and some portions of the temporal fossa and infratemporal fossa. The zygomatic bone can withstand the forces of mastication and transmitting reactionary forces from the maxilla. It gives rise to the masseter muscle, which is the major jaw adductor in mammals. Each zygomatic bone has three surfaces (orbital, temporal, and lateral), four

borders (orbital or antero-superior, maxillary or antero-inferior, temporal or postero-superior, zygomatic, or postero-inferior), and three processes (frontal, temporal, and maxillary). The bone houses the zygomatic canal leading to openings on the temporal (zygomaticotemporal foramen) and the facial surfaces (zygomaticofacial foramen) of the zygomatic bone. The zygomatic nerve, main nerve supply for the zygomatic bone which is branch of maxillary nerve, dividing into the branches and the zygomatic blood vessels pass through it; zygomaticofacial foramen is of clinical significance of the approach in discussion [Figure 1]. The two anthropological reference point: The Jugale (Ju) at the most concave point between the lateral margin of the zygomatic bone and the zygomatic arch and the Zygomaxillare (Zm) at the lowermost point of the zygomaticomaxillary suture is of clinical significance as trabeculae at Ju region is the thickest and Zm region containing fewer and thinner trabeculae elements making Ju region ideal for the fixture engagement [Figure 2]. The concavity between the frontal and temporal process of the zygomatic bone facilitates the 90° approach for the fixture engagement through the palatal approach,^[24] which makes the perfect zygomatic fixation with transsinus approach.

Infraorbital foramen located medially to zygomaticomaxillary suture and inferior to infraorbital rim houses infraorbital nerve and vessels, care to be taken in flap reflection for the zygomatic approach.

The vessels of clinical significance for the zygomatic approach include transverse facial, branch of superficial temporal artery, and facial artery. The transverse facial artery originates from the superficial temporal artery within the parotid gland and courses anteriorly to the cheek, over the zygomatic bone. Occasionally, it formed an anastomosis with the facial artery. The facial artery, branch of external carotid artery, travels to and curves around the inferior border of the mandible just anterior to the prominent masseter muscle. The facial artery is the main artery of the cheek providing several arterial branches to neighboring structures, including the skin areas of the chin, lips, and nose. The main arterial supply over the zygomatic bone is from arterial perforators originating from the transverse facial artery and facial artery. Facial vein drains from the infraorbital vein courses on average 15 mm posterior to the facial artery, being inferior to crista zygomaticoalveolaris.^[25] The determination of the zygomatic bone showed a medio-lateral thickness of 7.60 ± 1.45 mm for the females and 8.00 ± 2.26 mm for the male specimens,^[26] the mean length in this region is 14 mm^[27] which is sufficient for two zygomatic fixture placement. The palatal mucosa around the premolars and molar is around 5 mm thick which is of clinical importance keeping the abutment margin supragingival avoiding soft-tissue reaction.

Anatomical structures explained above are of clinical importance for the zygomatic implant approach, better understanding is utmost important to avoid intra-operative mishaps and manage complications with or without flap technique for zygomatic implant fixation.

Technique

The techniques common for zygomatic approach mainly are intra-sinus technique by Branemark (1998), sinus-slot technique from Stella and Warner (2000), extramaxillary Approach by Miglioranza *et al.*(2006) [Figure 3]. There was a shift from Branemark intrasinus with palatal emergence technique toward the placement technique having acceptable

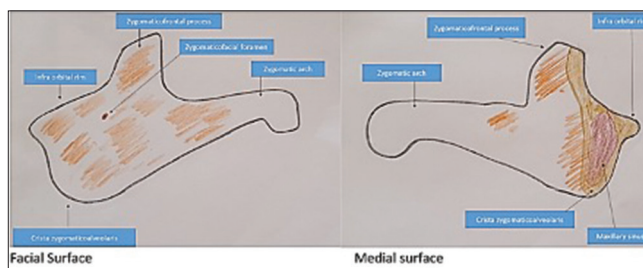


Figure 1: Zygomatic complex; Shaded areas are site for implant

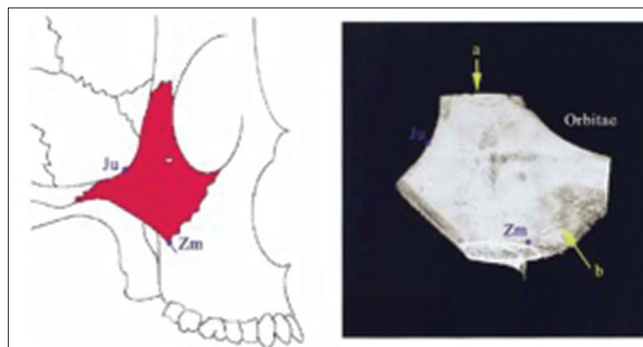


Figure 2: Jugale (Ju) and Zygomaxillare (Zm) (Kato *et al.* Internal Structure of Zygomatic Bone. J Maxillofac Surg 2005)

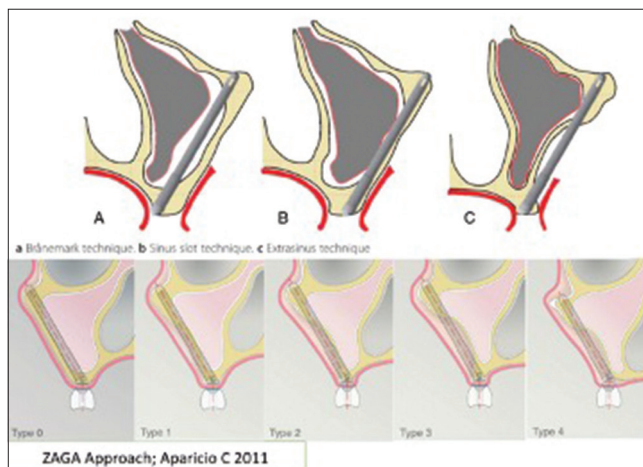


Figure 3: Zygomatic approaches

abutment position at the alveolar crest to achieve comfortable prosthetic solution and minimizing the cantilever by keeping the implant emergence intraorally toward first molar. Emphasis was made to have maximum contact with the anterior wall of the maxilla creating more bone to implant contact as been proposed by Stella and Warner and followed by Aparicio.

With single-piece zygomatic implant, concavity of the anterior wall of the maxilla and the alveolar ridge height defines the technique to be trans-sinus or extra-sinus approach. Here, the foremost aim is to keep the abutment emergence close to the alveolar ridge for the functionally acceptable prosthesis and least traumatic for patient keeping flapless if possible.

Presurgical evaluation

Maxillary sinus evaluation is done regarding the position of the zygomatic bone with respect to the maxillary ridge with computer tomogram, para-nasal-sinus view, orthopantomogram. Master cast is needed for planning the acceptable abutment emergence position. Routine pathological test mandatory as for the surgical protocol keeping the parameters acceptable and patient consent form to be acquired.

Armamentarium

Single-piece implant system (Simpladent and Ihde dental, Switzerland) 2.2 mm twist drill of length 50 mm and 55 mm. Implant placement aid and Hand grip Torque controlled ratchet Contra-angle 1:1 reduction Handpiece Physio-dispenser Routine surgical instruments for flap reflection and sutures.

Surgical technique

The main advantage with single-piece zygomatic implant is the freedom of placement in respect to the abutment emergence for the desired prosthetic placement because of bendable zone available in the fixture. Here, the placement is purely tactile based and the experience and anatomical knowledge of the surgeon is demanded when flapless intrasinus technique is approached. Almost all the zygomatic placement is done on routine dental setup under local anesthesia.

We broadly classify the zygomatic implant placement technique with single piece into (a) transsinus technique and (b) extrasinus approach.

The height of alveolar bone at premolars and molar available, the zygomatic bone in relation of maxilla are the important landmarks to be evaluated for trans-sinus or extramaxillary zygomatic approach. Infraorbital block, posterior superior nerve block, and greater palatine nerve block along with local infiltration at the lateral surface of zygomatic bone are done for both trans-sinus and extra-sinus technique.

Extra-sinus approach

It is also an open-flap approach. This technique is inspired from the techniques by Stella and Warner (2000) and Aparicio C (2011). Whenever an operator is in doubt always reflect the flap. This technique is preferred when simultaneously pathology or the foreign body from the maxillary sinus is to be excavated [Figure 4]. This technique is convenient to approach zygomatic bone for fixture engagement when there is available alveolar bone height at premolar and molar, the situation is present when zygomatic fixture is done as a rescue to reinforce the ailing implant system present [Figure 5].

Full-thickness flap is reflected exposing the infra-orbital foramen and cresta zygomaticoalveolaris, the extend of the flap depends upon the unilateral or bilateral zygomatic fixture placement. When unilateral, releasing vertical incision is made at maxillary midline or at piriform aperture and distal to the 1st molar extending till posterior of the zygomatic bone. When bilateral zygomatic fixture is demanded releasing incision is made distal of zygomatic bone bilaterally keeping the horizontal incision palatal to alveolar crest, degloving incision is also an ideal choice. Flap reflection is kept conservative when compared to conventional zygomatic approach where till the lateral orbital rim is exposed. Premolar site is the point of purchase from the alveolar bone directed toward the Jugale region ideally for osteotomy. Either the slot is made at anterior wall of maxilla lateralizing the Schinederian membrane or the osteotomy is just parallel to the anterior wall of the maxilla depending upon the concavity of anterior wall, extent of resorbed maxillary alveolar bone or the exteriorized zygomatic bone in relation to maxilla. Point of purchase is kept at the palatal margin of the alveolar crest or 6 mm toward palatal bone depending upon the available alveolar bone height and the

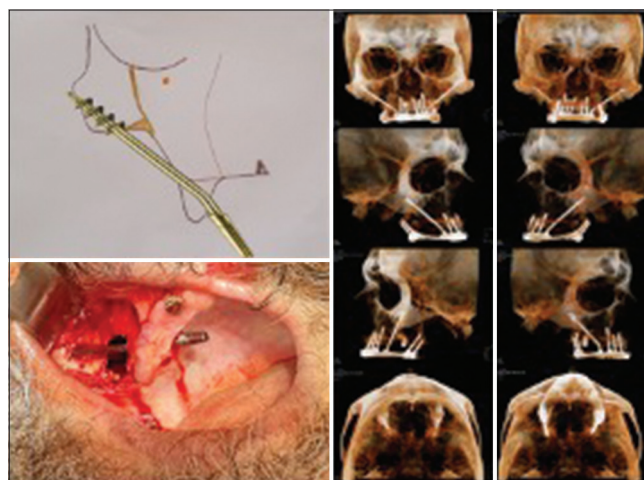

Figure 4: Extra-sinus approach with flap in conjunction with sinus pathology removal

concavity of anterior maxillary wall. 6 mm inferior to cresta zygomaticoalveolaris osteotomy is made to extend till the posterior of lateral surface of Zygoma, drill is exteriorized and is felt on the finger kept at the lateral surface and at jugale region. Length of the implant is determined observing the marked dimension on the osteotomy drill, from the exteriorized point till the point of purchase. This 6 mm minimal rule is very important according to the author for a zygomatic fixture of 4.6 mm diameter otherwise the threads of the single-piece zygomatic fixture will slip toward the lateral surface of zygoma or the alveolar crest making the correction difficult later on. Ideal zygomatic fixture placement is when the abutment emergence is on the palatal aspect of alveolar crest and apically engaged at the Jugale region, after bending abutment is repositioned on the alveolar crest. Zygomatic fixture is placed with the insertion tool attached with handgrip till the desired length. Zygomatic fixture is exteriorized till 1 mm or is engaged till the border of zygomatic bone. This hold true for zygomatic implant placement in high atrophy postresection case [Figure 6]. It is advisable to lateralize the Schinederian membrane and maintain its patency but if the rupture happens, it is of less clinical significance provided flap closure is achieved.

Trans-sinus approach

It is the least traumatic but high skill demanding approach as being flapless. This technique is inspired from the Branemark (1998) technique. The purchase point of the osteotomy at alveolar crest depends upon the extent of maxillary resorption, concavity of anterior maxilla, or the exteriorized zygoma in relation to the maxilla. With flat anterior wall and moderately resorbed maxilla, the flapless approach is the easiest, but in the case of severe maxillary resorption or with profound concavity of anterior maxilla, this approach is very skillful demanding [Figure 7]. Depending upon the extent of concave anterior maxilla or alveolar bone height available, point of osteotomy is at the palatal aspect of alveolar crest or toward the palatal bone; more the height and concavity more palatal is the point of osteotomy [Figure 8]. With transsinus technique, an operator always achieves the ideal engagement of zygomatic fixture at jugale or confluence of frontal and zygomatic process, the angulation achieved is almost perpendicular to the targeted bone by the fixture. Length of the zygomatic implant corresponds to the osteotomy drill marking from alveolar palatal crest to the exteriorized at zygomatic bone felt from the finger. It is important to note that any angulation $<45^\circ$ in relation to the palatal plane will lead the osteotomy drill slipping toward infratemporal fossa and vertically more than 50° will lead toward the orbit. When the osteotomy is done at or distal to upper 1st molar, it is more than 50° angulated vertically, and it reaches close or at orbital floor, thus the care is utmost.

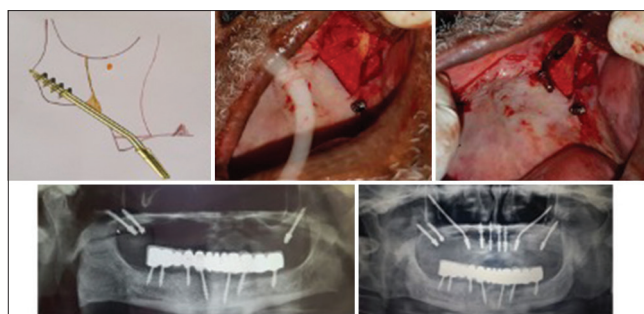


Figure 5: Extra-sinus Approach as rescue implant

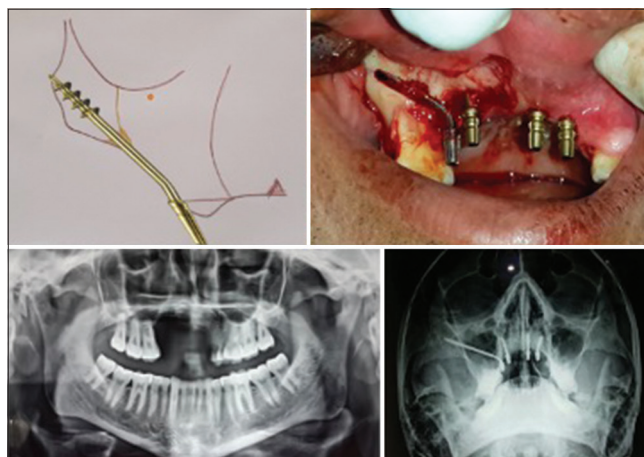


Figure 6: Extra-sinus Approach for post resection cases

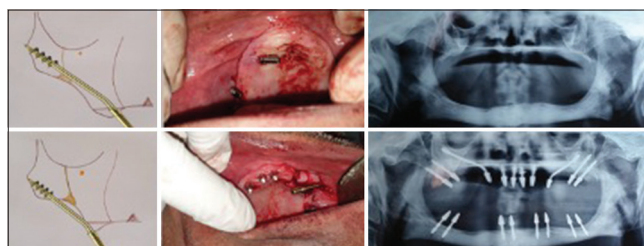

Figure 7: Figure presenting intra and extrasinus approach

In ultra-resorbed maxilla, after zygomatic implant placed at one side its not advisable to bent the abutment till the contralateral side fixture is placed as when the abutment is upright, it interfere in the contralateral approach with the hand grip.

When more than one zygomatic fixture is placed, always the anterior which is lengthier is placed first and should be engaged cranially at zygomatic bone so that the posterior is engaged inferior to anterior at zygomatic bone, the osteotomy approach is at least 6 mm distal to the anterior at alveolar crest or palatal aspect [Figure 9].

It is advisable placement of zygomatic implant flapless with surgical guide, but the author believes more on the tactile perception and when the splint is at mucosal

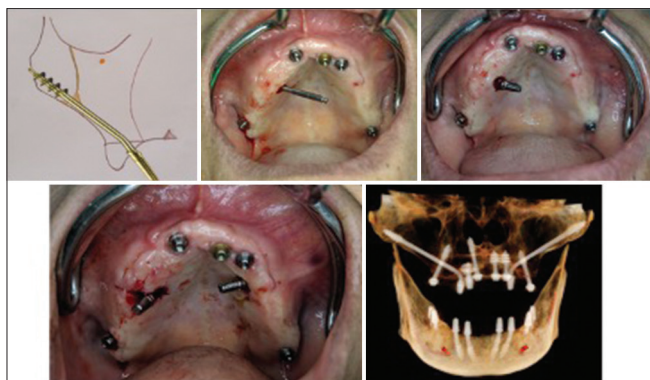


Figure 8: Trans-sinus approach in high alveolar condition

or bone level, a small change in orientation will lead the dramatic error in desired angulation leading to unwanted complication.

DISCUSSION

Immediate loading is the key and advantage with single-piece smooth surface implantology such as ZDI®. Delayed complications such as abutment screw loosening, abutment screw fracture, peri-implantitis, and palatal emergence of the abutment jeopardizing the prosthetic system are avoided with the technique. There is enough evidence and studies in support of immediate loading (Buser *et al.* 1988; Piatelli *et al.* 1993; Henry and Rosenberg 1994; Salama *et al.* 1995; Bijlani and Lozada 1996; Chiapasco *et al.* 1997; Tarnow *et al.* 1997; Randow *et al.* 1999; Scortecchi 1999; Ericsson *et al.* 2003; Malo *et al.* 2000; and Ihde 2009; Shan *et al.* 2013).^[28,29] When primary stability is achieved and a proper prosthetic treatment plan is followed, immediate functional loading is a feasible concept. Clinically, the host bone density plays an important role in determining the predictability of the immediate loading success. Trabecular density of edentulous zygomatic is higher in the jugale region and consists of plate-like structure. Stresses caused by muscles are concentrated in the jugale region of edentulous zygomatic bone because of the adherence of the masseter muscles and fascia temporalis to zygomatic bone. Osteocytes in the bone matrix act as pressure sensors and that there is a pressure sensory network among osteocytes, osteoblast, and osteoclasts. The stress caused by the associated muscles prevents the generation of osteocytes and increases the activation of osteoblasts in the zygomatic bone of edentulous maxillae making it ideal for immediate loading for fixtures.^[30,31] The screw shape design of the single-piece ZDI® not only minimizes micromotion but also improves the initial stability, the principle requirement for immediate loading success. Primary stability can be enhanced when cross-arch implant splinting is performed and is recommended in immediate implant loading.^[32-38] There seems to be sufficient evidence emerging to support a

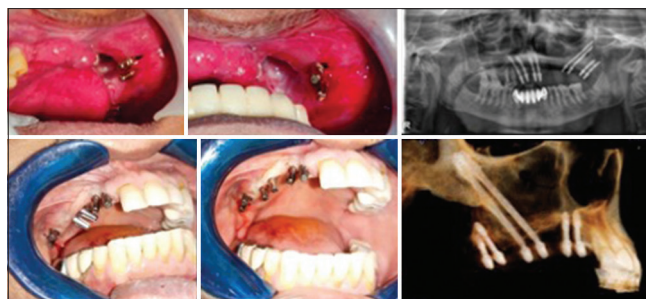

Figure 9: Flapless double zygomatic approach

one-stage nonsubmerged protocol which can achieve success rate comparable to implants placed in two-staged submerged procedure.^[39-43] Osteotomy when made for zygomatic fixture with or without flap is devoid of irrigation. It has been shown that a temperature over 47°C for 1 min causes “heat necrosis” in the bone.^[44] However, increasing both the speed and the load together allowed for more efficient cutting with no significant increase in the temperature.^[45] Thus, the speed around 40 thousand rpm with 1:1 reduction handpiece is advisable for the cortical osteotomy.

The emergence of the smooth surface single-piece zygomatic fixture at palatal aspect does not create adverse tissue reaction, leading to mucositis, crestal bone loss, and peri-implantitis as thickness of the keratinized tissue is around 5 mm, in severe atrophic cases, the buccinator muscle attachment is present at the vestibular aspect. The supragingival abutment level is always advantageous. Biofilm is a microbial-derived sessile community, characterized by the cells that are irreversibly attached to a substratum or interface to each other, embedded in a matrix of extracellular polymeric substance produced by microbes. The biofilm attracts the plaque and so does the bacterial colonization that clinically manifests as reversible mucositis and irreversible peri implantitis which is one of the most common cause of osseointegrated surface treated implant failures and late complications.^[46] The biological seal that is formed by the mucosa surrounding smooth surface dental implants is established to provide protection against the microbial invasion.^[47] The trans-sinus implants placement does not lead to delayed postoperative complication. Immediate complication such as nasal bleeding, paresthesia, and burns of the skin or labial mucosa is manageable. Zhong *et al.*^[48] in their study observed the direct attachment of sinus membrane to the implant, forming the barrier to the sinus cavity. Petruson^[49] used sinuscopy of the maxillary sinuses of 14 patients with machined surface zygomatic implants, placed with no particular care regarding whether or not membrane disruption occurred and found no signs of adverse reactions. Petruson^[49] concluded to have no increased risk of inflammatory reactions in the normal nasal and maxillary

mucosa in the regions where titanium implant passes through the mucosa. The nitric oxide produced in the maxillary sinuses may therefore be another important explanation of why no infections are found around titanium implants.^[50-52]

It is assumed that the only stability of the zygomatic implant is derived from the zygomatic bone. The stress caused by occlusal forces is supported mainly through the zygoma. The stress from these forces is transferred predominantly through the infra-zygomatic crest and divided to the frontal and temporal process of the zygomatic bone. The remainder of the implant along with the abutment constitutes a considerable cantilever. These implants are never intended to be free-standing pillars, immediate, rigid, cross arch stabilization is recommended to prevent micromotion. Brunski^[53,54] and Meredith^[55] suggested in their studies that cross arch stabilization with rigid splinting appears to effectively reduce mechanical stress on the implants by reducing their movement. Thus, the zygomatic implant when rigidly cross arch splinted with anterior and posterior implants such as premaxillary implants and pterygoids, effectively transfer the masticatory load to anterior and posterior implants and resisting lateral/offset loading.^[38] Additional implants placement to avoid cantilever extension significantly lower the stress values.^[56,57] Posterior cantilever on implant prosthesis produce complications, including screw fractures, prosthesis fractures, bone loss, and loss of osseointegration.^[58] Improving biomechanical stability and load distribution by means of noncantilevered, bone anchored restorations should enhance the long-term prognosis of implant restorations in the posterior maxilla.^[59,60] The rationale for placement of 8 or more implants to support a fixed complete arch prosthesis in the maxilla is supported by Kopp's analysis of various studies on implant restorative predictabilities.^[61] Bahat recommended placement of a sufficient number of implants to support the occlusal load in a way that avoids nonaxial loading.^[62]

One of the most serious and prevalent problems associated with the restorative aspect of dental implants is loosening and fracturing of the screws. McGlumphy *et al.*^[63] defined the screw joint as two parts tightened together by a screw, such as an abutment and implant being held together by a screw. Screw preload, clamping force, joint-separating force, and settling effect are the factors maintaining the dynamics of screw connection. When the settling effect is greater than the elastic elongation of the screw, the screw work loses because there is no longer any contact to hold it in place. The initial surface roughness of the screw, surface hardness, and magnitude of loading forces (offset forces and cantilever situation) are the factors affecting the stability of the connection.^[64] With single-piece implants such delayed

complications can be avoided with cross arch fixation and maintaining strategic occlusion^[38] [Figure 10].

There are surgical advantages to both the single-stage guided surgery and single-stage free hand approaches. The freehand techniques allow the ability to adjust or re-angle the osteotomy site based on what the surgeon encounters. In addition, the free-hand technique offers better firsthand visualization of the surgical site and the opportunity to alter bone or soft tissue while the mucosa is reflected when necessary.^[65] Moon *et al.*^[66] calculated the mean angular errors between the preoperative planned and postoperative placed implant was 3.84 ± 1.49 degree, Di Giacomo *et al.*^[67] calculated an angular error of 7.25 ± 2.67 degrees. Particularly, for an angular error, the utilization of surgical guides as a tooth support was reported to result in a smaller angular error than that of bone support and a mucosa support. The longer implants such as zygomatic fixtures with such angular error may lead to apical deviation missing the intended anchorage site, the author prefer the free hand placement based on tactile perception rather than the computerized tomogram guided surgical guide, but it is the individual's preference based on the experience.

Single-piece implantology after wide spread diffusion in the second half of the last century saw its application significantly reduced by dental implantologists. The main reason of a progressive reduction was the Branemark concept of implant osseointegration, although now the most recent knowledge allows reducing the timing on implant loading.^[68] Garbaccio,^[16] Scortecci,^[69] and Ihde^[18,29,38,70,71] with their work have successfully reestablished single-piece implantology. Awadalkreem *et al.*^[72] have shown in their work patient's satisfaction with comfort, mastication, speech, and esthetics significantly improved with the new basal implants, single-piece smooth surface implants.

SUMMARY

Single piece zygomatic implant, or a remote anchorage implant, is an effective tool for rehabilitation of the atrophic/

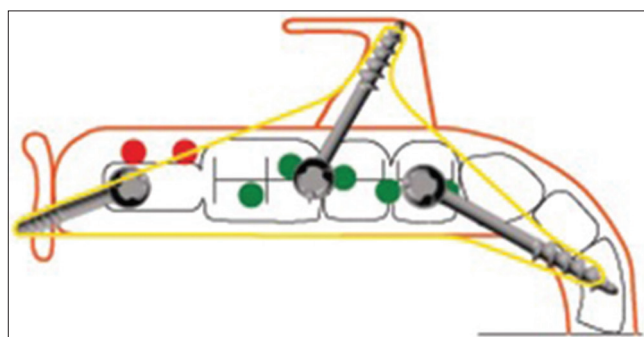


Figure 10: Tripodization achieved from zygomatic fixture

resected jaws with least postoperative complications such as screw loosening, screw fractures, bone loss, mucositis, and peri-implantitis. Zygomatic fixtures avoid the grafting procedures and cantilever situation, restoration of atrophic or postablative jaws are completed with immediate loading. The author has presented in this article simplified and practical free-hand approach for the implant placement in zygomatic bone which he has learned by improvising after each zygomatic implant surgery completed successfully. With respect to the advantages of the single-piece zygomatic implant discussed above, it has an effective role in resection cases rehabilitation and thus rightly termed as oncology implant.^[73]

Financial support and sponsorship

Nil.

Conflicts of interest

There are no conflicts of interest.

REFERENCES

- Cawood JL, Howell RA. A classification of the edentulous jaws. *Int J Oral Maxillofac Surg* 1988;17:232-6.
- Schnitman P, DaSilva J, Wöhrle P, Wang H, Koch G. Influence of site on implant survival: Seven-year results. *J Dent Res* 1993;72:311.
- Isaksson S, Alberius P. Maxillary alveolar ridge augmentation with onlay bone grafts and immediate endosseous implants. *J Craniomaxillofacial Surg* 1992;20:2-7.
- Van Steenberghe D, Naert I, Bossuyt M, De Mars G, Calberson L, Ghyselen J, et al. The rehabilitation of the severely resorbed maxilla by simultaneous placement of autogenous bone grafts and implants: A 10 year evaluation. *Clin Oral Invest* 1997;1:102.
- Jensen OT, Shulman LB, Block MS, Iacono VJ. Report of the Sinus Consensus Conference of 1996. *Int J Oral Maxillofac Implants* 1998;13 Suppl: 11-45.
- Boyne PJ, James RA. Grafting of the maxillary sinus floor with autogenous marrow and bone. *J Oral Surg* 1980;38:613.
- Sailer HF. A new method of inserting endosseous implants in totally atrophic maxillae. *J Craniomaxillofacial Surg* 1989;17:299.
- Kahnberg KE, Nilsson P, Rasmussen L. Le Fort I osteotomy with interpositional bone grafts and implants for rehabilitation of the severely resorbed maxilla: A 2-stage procedure. *Int J Oral Maxillofac Implants* 1999;14:571.
- Nystrom E, Lundgren S, Gunne J, Nilson H. Interpositional bone grafting and Le Fort I osteotomy for reconstruction of the atrophic edentulous maxilla: A two stage technique. *Int J Oral Maxillofac Implants* 1997;26:423.
- Isaksson S, Ekfeldt A, Alberius P, Blomqvist JE. Early results from reconstruction of severely atrophic (class VI) maxillas by immediate endosseous implants in conjunction with bone grafting and Le Fort I osteotomy. *J Oral Maxillofac Surg* 1993;22:144-8.
- Adell R, Lekholm U, Gröndahl K, Brånemark PI, Lindström J, Jacobsson M. Reconstruction of severely resorbed edentulous maxillae using osseointegrated fixtures in immediate autogenous bone grafts. *Int J Oral Maxillofac Implants* 1990;5:233-46.
- Farzad P, Andersson L, Gunnarsson S, Johansson B. Rehabilitation of the severely resorbed maxillae with zygomatic implants: An evaluation of implant stability, tissue conditions, and patient's opinion before and after treatment. *Int J Oral Maxillofac Implants* 2006;21:399-404.
- Widmark G, Andersson B, Carlsson GE, Lindvall AM, Ivanoff CJ. Rehabilitation of patients with severely resorbed maxillae by means of implants with or without bone grafts: A 3- to 5-year follow-up clinical report. *Int J Oral Maxillofac Implants* 2001;16:73-9.
- Winegar BA, Murillo H, Tantiwongkosi B. Spectrum of critical imaging findings in complex facial skeletal trauma. *Radiographics* 2013;33:1.
- Sorní M, Guarinos J, Peñarrocha M. Implants in anatomical buttresses of the upper jaw. *Med Oral Patol Oral Cir Bucal* 2005;10:163-8.
- Garbaccio D. Endosseous self-threading screws: Biomechanical principles, surgical technic and clinical results. *Dent Cadmos*. 1981;49:19-31.
- Chiapasco M, Gatti C, Rossi E, Haefliger W, Markwalder TH. Implant-retained mandibular overdentures with immediate loading. A retrospective multicenter study on 226 consecutive cases. *Clin Oral Implants Res* 1997;8:48-57. doi: 10.1111/j.1600-0501.1997.tb00007.x. PMID: 9586456.
- Ihde S. Indications and treatment modalities with corticobasal jaw implants. *Ann Maxillofac Surg* 2019;9:379-86.
- Brånemark PI. *Surgery and Fixture Installation: Zygomatic Fixture Clinical Procedures*. 1st ed. Goteborg, Sweden: Nobel Biocare AB; 1998. p. 1
- Malevez C, Daelemans P, Adriaenssens P, Durdu F. Use of zygomatic implants to deal with resorbed posterior maxillae. *Periodontol* 2000 2003;33:82-9.
- Chow J, Hui E, Lee PK, Li W. Zygomatic implants – Protocol for immediate occlusal loading: A preliminary report. *J Oral Maxillofac Surg* 2006;64:804-11.
- Bedrossian E, Rangert B, Stumpel L, Indresano T. Immediate function with the zygomatic implant: A graftless solution for the patient with mild to advanced atrophy of the maxilla. *Int J Oral Maxillofac Implants* 2006;21:937-42.
- Migloriança RM, Ilg JP, Mayo TM, Serrano AS, Funis LP, et al. Função imediata em fixações zigomáticas: Relato de dois casos com 18 e 30 meses de acompanhamento clínico. *Implant News* 2006;3:243-7.
- Kato Y, Kizu Y, Tonogi M, Ide Y, Yamane GY. Internal structure of zygomatic bone related to zygomatic fixture. *J Oral Maxillofac Surg* 2005;63:1325-9.
- Von Arx T, Tamura K, Yukiya O, Lozanoff S. The Face – A Vascular Perspective, A literature review. *Swiss Dent J* 2018;128:382-92.
- Nkenke E, Hahn M, Lell M, Wiltfang J, Schultze-Mosgau S, Stech B, et al. Anatomic site evaluation of the zygomatic bone for dental implant placement. *Clin Oral Implants Res* 2003;14:72-9.
- Candel E, Peñarrocha D, Peñarrocha M. Rehabilitation of the atrophic posterior maxilla with pterygoid implants: A review. *J Oral Implantol* 2012;38 Spec No: 461-6.
- Gapski R, Wang HL, Mascarenhas P, Lang NP. Immediate implant loading. *Clin Oral Impl Res* 2003;14:515-27.
- Ihde S. No more sinus-lift. *CMF Impl Dir* 2009;4:160-74.
- Weinbaum S, Cowin SC, Zeng Y. A model for the excitation of osteocytes by mechanical loading-induced bone fluid shear stresses. *J Biomech* 1994;27:339.
- Deborah MJ, Hillam RA, Timothy SM. Constitutive *in vivo* mRNA expression by osteocytes of beta-actin, osteocalcin, con nexin-43, IGF-I, c-fos and c-jun, but not TNF-alpha nor tartrate – Resistant acid phosphatase. *J Bone Miner Res* 1996;11:350-7.
- Ledermann PD. Stegprothetische Versor- gung des zahnlosen Unterkiefers mit Hilfe von plasmabeschichteten Titanischaubenimplantaten. *Dtsch Zahmarzhliche Z* 1979;34:907-11.
- Ledermann PD. Sechsjah- rige klinische Erfahrung mit dem titanplasmabeschichteten ITI-Schraubenimplantat in der Regio interforami- nalis des Unterkiefers. *Schweiz Monatsschr Zahnmed* 1983;93:1080-9.
- Salama H, Rose LF, Salama M, Betts NJ. Immediate loading of bilaterally splinted titanium root-form implants in fixed prosthodontics – A

- technique reexamined: two case reports. *Int J Periodontics Restorative Dent* 1995;15:344-61.
35. Spiekermann H, Jansen VK, Richter EJ. A 10-year follow-up study of IMZ and TPS implants in the edentulous mandible using bar-retained overdentures. *Int J Oral Maxillofac Implants* 1995;10:231-43.
 36. Tarnow DP, Emtiaz S, Classi A. Immediate loading of threaded implants at stage 1 surgery in edentulous arches: Ten consecutive case reports with 1- to 5-year data. *Int J Oral Maxillofac Implants* 1997;12:319-24.
 37. Randow K, Ericsson I, Nilner K, Petersson A, Glantz PO. Immediate functional loading of Brånemark dental implants. An 18-month clinical follow-up study. *Clin Oral Implants Res* 1999;10:8-15.
 38. Ihde S, Ihde A, Lysenko V, Konstantinovic V, Palka L. Systematic terminology of cortical bone areas for osseointegrated implants in strategic oral implantology. *J Anatomy* 2016;1:007.
 39. Henry P, Rosenberg I. Single-stage surgery for rehabilitation of the edentulous mandible: Preliminary results. *Pract Periodontics Aesthet Dent* 1994;6:15-22.
 40. Ericsson I, Randow K, Glantz PO, Lindhe J, Nilner K. Some clinical and radiographical features of submerged and non-submerged titanium implants. *Clin Oral Implants Res* 1994;5:185-9.
 41. Becker W, Becker BE, Israelson H, Lucchini JP, Handelsman M, Ammons W, *et al.* One-step surgical placement of Brånemark implants: A prospective multicenter clinical study. *Int J Oral Maxillofac Implants* 1997;12:454-62.
 42. Ericsson I, Randow K, Nilner K, Petersson A. Some clinical and radiographical features of submerged and non-submerged titanium implants. A 5-year follow-up study. *Clin Oral Implants Res* 1997;8:422-6.
 43. Buser D, Mericske-Stern R, Dula K, Lang NP. Clinical experience with one-stage, non-submerged dental implants. *Adv Dent Res* 1999;13:153-61.
 44. Eriksson AR, Albrektsson T. Temperature threshold levels for heat-induced bone tissue injury: A vital-microscopic study in the rabbit. *J Prosthet Dent* 1983;50:101-7.
 45. Brisman DL. The effect of speed, pressure, and time on bone temperature during the drilling of implant sites. *Int J Oral Maxillofac Implants* 1996;11:35-7.
 46. Subramani K, Jung RE, Molenberg A, Hammerle CH. Biofilm on dental implants: A review of the literature. *Int J Oral Maxillofac Implants* 2009;24:616-26.
 47. Neiva RF, Neiva KG, Oh TJ, Wang HL. Clinical and morphological aspects of the implant/soft tissue interface. *Int Chin J Dent* 2002;2:151-61.
 48. Zhong W, Chen B, Liang X, Ma G. Experimental study on penetration of dental implants into the maxillary sinus in different depths. *J Appl Oral Sci* 2013;21:560-6.
 49. Petruson B. Sinuscopy in patients with titanium implants in the nose and sinuses. *Scand J Plast Reconstr Surg Hand Surg* 2004;38:86-93.
 50. MacMicking J, Xie QW, Nathan C. Nitric oxide and macrophage function. *Annu Rev Immunol* 1997;15:323-50.
 51. Runer T, Cervin A, Lindberg S, Uddman R. Nitric oxide is a regulator of mucociliary activity in the upper respiratory tract. *Otolaryngol Head Neck Surg* 1998;119:278-87.
 52. Awadalkreem F, Ahmad AG, Ihde S, Osman M. Effects of corticobasal implant protrusion inside the nasal and maxillary sinus. *Ann Maxillofac Surg* 2020;10:114-21.
 53. Brunski JB. Biomechanics of oral implants: Future research directions. *J Dent Educ* 1988;52:775-87.
 54. Brunski JB. Biomaterials and biomechanics in dental implant design. *Int J Oral Maxillofac Implants* 1988;3:85-97.
 55. Meredith N. Assessment of implant stability as a prognostic determinant. *Int J Prosthodont* 1998;11:491-501.
 56. Krekmanov L. Placement of posterior mandibular and maxillary implants in patients with severe bone deficiency: A clinical report of procedure. *Int J Oral Maxillofac Implants* 2000;15:722-30.
 57. Chakranarayan A, Soni P, Kapri A, Kumar R. Effectiveness of strategic corticobasal implants in the management of edentulism. *IP Ann Prosthodont Restor Dent* 2020;6:77-86.
 58. Balshi TJ. Preventing and resolving complications with osseointegrated implants. *Dent Clin North Am* 1989;33:821-68.
 59. Rangert B, Krogh PH, Langer B, Van Roekel N. Bending overload and implant fracture: A retrospective clinical analysis. *Int J Oral Maxillofac Implants* 1995;10:326-34.
 60. Rangert B, Jemt T, Jörneus L. Forces and moments on Branemark implants. *Int J Oral Maxillofac Implants* 1989;4:241-7.
 61. Kopp CD. Brånemark osseointegration. Prognosis and treatment rationale. *Dent Clin North Am* 1989;33:701-31.
 62. Bahat O. Brånemark system implants in the posterior maxilla: Clinical study of 660 implants followed for 5 to 12 years. *Int J Oral Maxillofac Implants* 2000;15:646-53.
 63. McGlumphy EA, Mendel DA, Holloway JA. Implant screw mechanics. *Dent Clin North Am* 1998;42:71-89.
 64. Winkler S, Ring K, Ring JD, Boberick KG. Implant screw mechanics and the settling effect: Overview. *J Oral Implantol* 2003;29:242-5.
 65. Balshi TJ, Wolfinger GJ, Schlauch RW, Balshi SF. A retrospective comparison of implants in the pterygomaxillary region: Implant placement with two-stage, single-stage, and guided surgery protocols. *Int J Oral Maxillofac Implants* 2013;28:184-9.
 66. Moon SY, Lee KR, Kim SG, Son MK. Clinical problems of computer-guided implant surgery. *Maxillofac Plast Reconstr Surg* 2016;38:15.
 67. Di Giacomo GA, Cury PR, de Araujo NS, Sendyk WR, Sendyk CL. Clinical application of stereolithographic surgical guides for implant placement: Preliminary results. *J Periodontol* 2005;76:503-7.
 68. Spitaleri D, Franco LPR, Zamolo L. New concept and a new perspective in the use of one piece dental implants. *J Orthod Craniofac Res* 2020;2:108. DOI: 10.29011/JOCR-108.100108.
 69. Gerard M. Basal Implantology. Springer International Publishing; 2019. 978-3-319-44873-2.
 70. Ihde S. Principles of BOI. 1st ed. Heidelberg: Springer; 2005.
 71. Ihde S, Palka L. Anchorage possibilities in case of a unilateral maxillary defect using the concept of Strategic Implant®. *Natl J Maxillofac Surg* 2018;9:235-9.
 72. Awadalkreem F, Khalifa N, Satti A, Suleiman AM. The influence of immediately loaded basal implant treatment on patient satisfaction. *Int J Dent* 2020;2020:6590202. doi: 10.1155/2020/6590202. eCollection 2020.
 73. Vivek G, Anita D, Lukasz P. Mandibular reconstruction using single piece zygomatic implant in conjunction with a reinforcing Fibular Graft Union: A case report. *Int J Surg Case Rep* 2020;73:347-54.