Ihde & Ihde

Cookbook Mastication

5th Revised Edition

How to let your patients chew successfully
(not only) on a Strategic Implant®

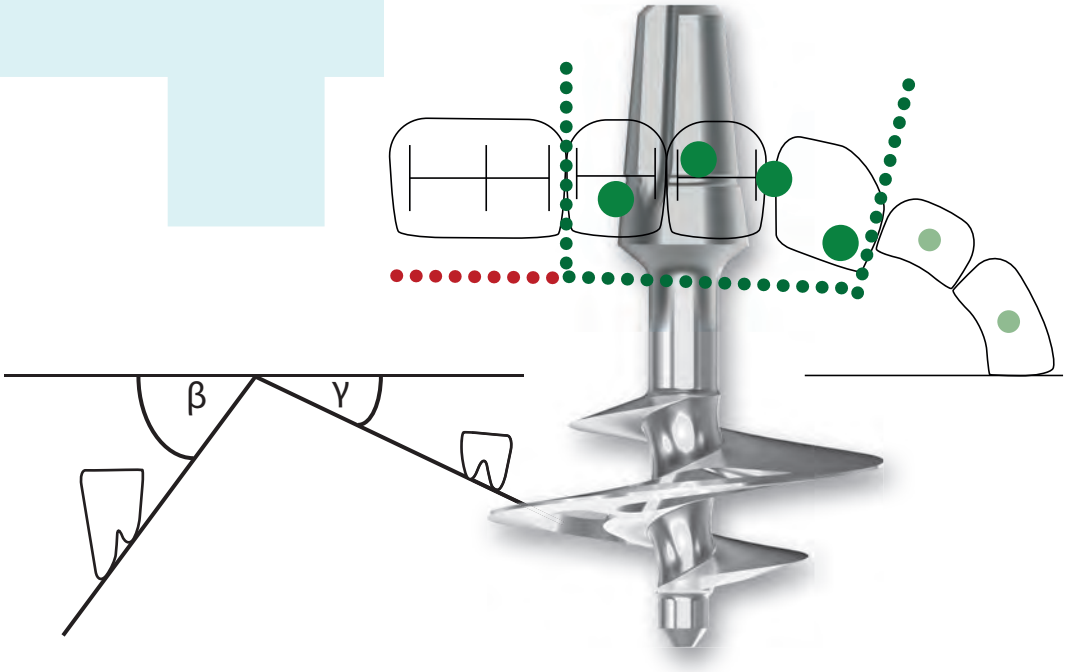

After reading and understanding this book you will be able to

- Establish an equal, bilateral masticatory function in every patient
- Safely determine the correct bite and rest position of the mandible
- Incorporate safely prosthetic work-pieces on immediately loaded jaw implants
- Correct the masticatory situation in case a mobility of the bridges on immediately loaded implants occurs
- Maintain the implant's stability and maintain a lateral pattern of mastication over years

International Implant Foundation Publishing

Cookbook Mastication

Ihde & Ihde

International Implant Foundation
Munich, Germany

Cookbook Mastication

Editors and Authors of this book

Prof. Dr. Stefan K.A. Ihde
Dr. Antonina A. Ihde

This work is subject to copyright. All rights reserved, whether the whole or part of the material is concerned, specifically the rights of translation, reprinting or reuse of illustrations, recitation, broadcasting, reproduction on microfilms or in any other way, and storage in data banks. Duplication of this publication or parts thereof is permitted only under the provisions of the German Copyright Law of September 9, 1965, in its current version, and written permission must be always obtained from the editors, and all relevant authors and the International Implant Foundation. Violations are liable for prosecution under the German Copyright Law.

© The International Implant Foundation, Munich, Germany, 2021
5th English Edition: ISBN 978-3-945889-28-2

The use of general descriptive names, registered names, trademarks, etc. in this publication does not imply, even in the absence of a specific statement, that such names are exempt from the relevant protective laws and regulations and therefore free for general use.

Product liability The publisher cannot guarantee the accuracy and applicability of the devices and the technique on the individual case. In every individual case the user must check such information by consulting the relative literature.

Disclaimer While the advice and information in this book are believed to be true and accurate at the time of submission for publication, neither the authors nor the publisher can accept any legal responsibility for any errors or omissions made in any part of this book. The material presented in this book is not intended to represent the only method or application appropriate for the medical situations discussed but rather is intended to present an approach, viewpoint, statement or opinion of the authors, which may be helpful to others who encounter similar clinical situations. The opinions expressed, suggestions made and advice given in this book are those of the respective authors and not necessarily those of the publisher. The publisher and the authors make no warranty, express or implied, with respect to any material contained therein.

Due to the rapid development of medical knowledge, the authors recommend that this book be used only for a maximum of three years after its publication. An updated edition should be available by the end of this period, in which questions regarding the current state of knowledge will be answered. This book series is designed as a practical teaching script, which is why an extensive literature set has been dispensed with.

Foreword

In this 4th edition of the cookbook, we clarified numerous details and aspects that raised questions during the courses.

In this edition, we also tried to put more emphasis on general body statics, and we have described this complex as far as we are certain on this issue. Prosthetics textbooks often contain large (but usually useless) chapters on this topic. On the one hand, the dental books on this subject suggest that we first positively influence the general statics (before we treat), but they do not tell how this should be done in detail and (above all) how the success of the measures is measured.

In the Cookbook, we limited ourselves to comments for the head and neck area and tried to redefine the immediate components that create the functions for the lower jaw and the influencing components.

Unfortunately, maintaining joint health and skeletal health is not a priority in our western health systems. A large number of orthopaedic surgeons are not interested in improvements in this area and their surgical work is well paid. They form a solvent lobby group.

Little attention is paid in Western medicine to the fact that muscles have served as a storage medium for information for millions of years (long before the development of the cerebrum). This is still the case today: the German language has a very significant expression for it, one speaks of "the shock shoots into one's limbs" and also that we are "paralyzed by fear". Well, where does the shock shoot into effectively: into the muscles, it is the muscles that are paralyzed/hardened, and it can hold on there until (local) relaxation measures remove the (in principle permanent) hardening that has arisen. In this respect, we can be sure that the psyche has a massive impact on statics and posture. This rather straightforward description of the situation is also available in the English language (one would use "paralyzed by fear" there), while in the Russian language terms such as парализован страхом and его охватил страх use. The situation is therefore more than known around the world, but it is rarely taken into account, and corresponding damage and signs of damage are rarely adequately dealt with and in full cognition of the problem. Instead, the final treatment is carried out by orthopaedic surgery.

This fact is mentioned here and described because general muscular changes (e.g. as described above) of course determine the head position (based on the posture) and of course also the attitude to life (EN: attitude; RU: отношение к жизни). Changes in posture can therefore

be attributed to environmental influences, and you can have a strong (but hardly detectable with our means of diagnostics) influence on the treatment result. So things happen covertly, and apparently in many languages there are words for these facts and they are used, even if they are no longer understood in depth by everyone at the moment.

For our patient symmetry in body statics and movement is vital however, because a bilateral and equal pattern of chewing is required to maintain the implant's stability.

Different aspects of the AFMP-Concept were added, as well as the concept of the APPI which describes the situation in anterior-posterior direction. We consider this topic now as fully explained.

For a full understanding of the matter at least three complete readings of this booklet, accompanied with daily work in the field are necessary. Good luck!

Vrba/Tudorovici
May 2020

Contents

Chapter 1 Aim of the Treatment 12

1.1 The Functional Aim 12

1.2 Definitions and Background Information 12

1.3 Necessary Chewing Surfaces 18

1.4 Surfaces of the Hardware 2 which should never be in contact with the opposing dentition 18

Angle Class I 19

Angle Class II 20

Angle Class III 24

1.5 A Sufficient Vertical Dimension Allows "Mechanical Harmony" 27

1.6 The AFMP concept 31

1.6.1 Three rules of Dr. Pedro Planas 34

1.6.2 Considerations regarding the AFMP and lateral crossbites 35

1.7 The APPI Concept 36

1.7.1. Description 37

1.7.2. Case Study 39

1.7.3. Clinical implications 41

1.7.4. Number of Teeth per Jaw and Segment 41

1.8 "Balanced" Mastication and the Supporting Polygon 43

1.8.1 Avoiding Mechanical Overload through Bridge Design and Implant Positioning 44

1.8.2. Avoiding Mechanical overload through Design of the Masticatory Function 45

1.9 Specifics of Tooth Morphology in the Lateral Lower Jaw 46

1.9.1. Lower 1st Molar 46

1.9.2. Lower 1st Premolar 48

Chapter 2 Treatment in an Ever changing Environment 49

2.1 Introduction 49

2.2 Why Is the Bite Almost Always Incorrect? 50

2.3 How to Recognize the Incorrect Bite 51

2.4 How do the Components of the Masticatory Apparatus Alter the Position of the Masticatory Surfaces? 52

2.4.1. The (Jaw) Bone 52

2.4.2. Changing Tooth Positions 53

2.4.3. Muscle Activity 54

2.4.4. Changes in the TMJ's Morphology 54

Chapter 3 Diagnosing the Masticatory System 57

3.1 Ineffective Diagnostic Procedures 57

3.2 Effective Diagnostic Procedures 57

3.3 Preparing Existing Occlusion and Mastication 59

Chapter 4 Bite Registration on Implants and Bridge Frames **60**

Chapter 5 Adjustment and build-up of occlusal and mastication surfaces **63**
5.1 Introduction **63**
5.2 Patient compliance and the reliability of patient proprioception **65**
5.3 Articulation paper and other diagnostic tools **66**
5.4 Objective of occlusal adjustments **67**
5.5 Some basic considerations **70**
5.6 Definition and explanation of some terms **72**
5.6.1 Contacts in occlusion **72**
5.6.2 Chewing marks during mastication **72**
5.6.3 Possible undesirable concept during protrusive movements **72**
5.7 Adjusting the occlusion **72**
5.8 Adjusting the masticatory function **74**
5.9 Variations of the adjustment procedure for existing anterior teeth in both jaws **75**
5.9.1 One is to leave the natural anterior contact in place **75**
5.9.2 As an alternative, the bite can be slightly raised **76**
5.10 Adjusting the protrusion and biting function **76**
5.11 Why do the occlusion and mastication surfaces have to be adjusted repeatedly – sometimes in one and the same session? **77**
5.12 Functionally generated paths (FGPs), Bennett angles, axial inclinations: how to record pathologies professionally **77**
5.13 Therapeutic aspects **78**
5.14 Observation of the closing movement and palpation of muscle strength and muscle sequence **79**
5.15 "Sound check" **79**
5.16 Eliminating functional blockage **80**
5.17 Summary **81**

Chapter 6 Maintenance of Good Mastication **82**
6.1 Check Up Procedures **82**
6.2 Active Corrections **82**
6.3 Grinding Mobilized Bridges **83**
6.4 Body Statics **85**

Chapter 7 Tongue Function **87**

Conclusion **90**

Chapter 1

Aim of the Treatment

1.1. The Functional Aim

For our treatment we have postulated the aim of a bilaterally equal mastication, i.e. a lateral pattern of chewing. We consider anterior patterns of chewing to be a malfunction and anterior contacts between upper and lower front teeth during lateral movement as undesirable and risky.

1.2. Definitions and Background Information

Let us first start with a few definitions regarding the static and the dynamic situation. Fig. 1.1 explains about the different components of the masticatory system and about other components and regulators which influence its functioning and this figure and the legend will be our companion throughout life.

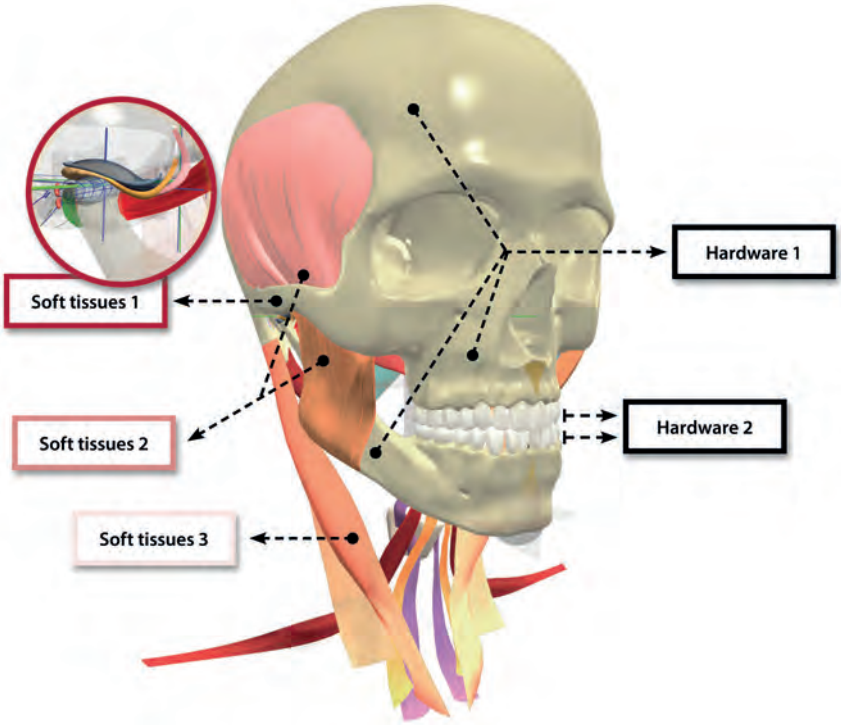

Fig. 1.1a *The masticatory system is created out of five principal components: (1) The maxillofacial skeleton and the mandible, here designated as* ***Hardware 1****. Hardware 1 underlies changes of bone morphology and the rules of bone prevail. (2) Teeth in the upper and lower jaw,* ***Hardware 2****. These components are underlying abrasion. Besides this teeth can intrude or extrude (with our without the surrounding bone and soft tissues), they can tilt or they can change their position. All these developments depend on the forces they are subjected to. Each component of Hardware 2 can change its spatial relationship independently from the others, and these changes are not underlying the Wolff`s Law. (3) System of the (adaptable) fibrous (TMJ) joints, the discs, tendons and chewing muscles (M. Masseter, Mm. Pterygoidei, M. Temporalis) are designated all together as* ***Soft Tissues 1****. The articular surfaces of the joints are here also considered soft tissues because they can change their shape over time, and these changes occur independently from the rules of bone (4) Components which carry out oro-facial functions and support the process of chewing. They are underlying various neuro-muscular feedbacks (Local mechanical regulators, working independently from the body posture,* ***Soft Tissues 2****. (5) Muscular system for the stabilization of the head posture and for creating an adequate environment for the mandible (General mechanical regulators working with dependency on the body posture,* ***Soft Tissues 3****.*

The temporo-mandibular joints are classified here as "Soft Tissues" because they easily undergo deformations and other alterations of their anatomy, which are not caused by reasons as described in Woff`s Law. This means that the upper end of the joint-process is a different entity than the rest of the mandible, also because the joints themselves can alter their morphology extremely fast and typically without developing pathologies which we know from all other joints in the human body. While morphological adaptations are not possible in all other human joints, the TMJ permits those necessary changes.

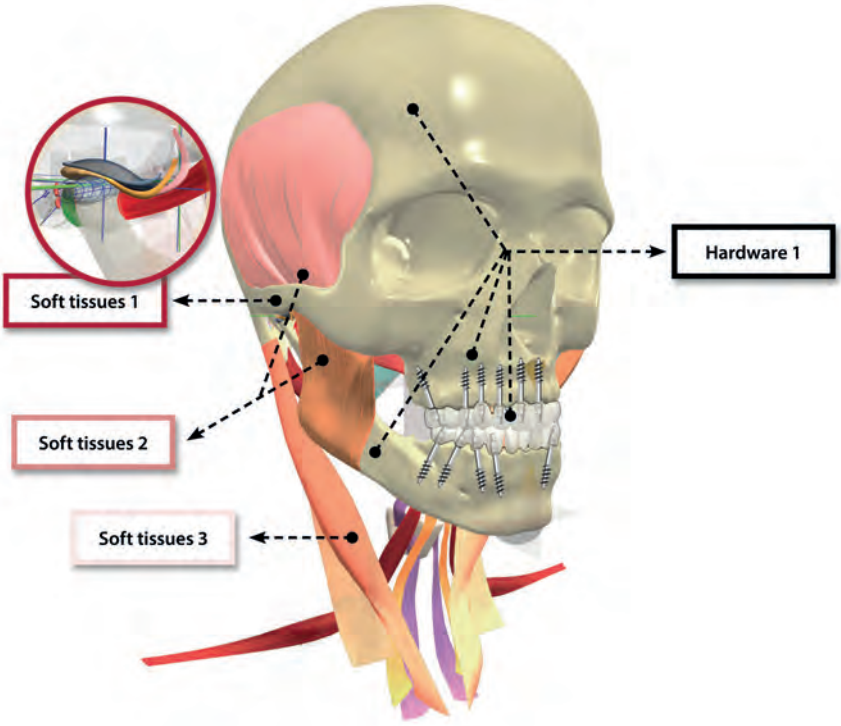

Fig. 1.1b *In implant borne reconstructions, regardless if they are osseointegrated or osseofixated, the teeth are (just as the implants) irreversibly connected to the bone. They can not elongate nor intrude or tilt, and they follow only the rules of the bone.*

Occlusal Centric

In occlusal centric (static situation, created by the Hardware 2 only, without influence of the TMJ; Maximum inter-cuspidation reached without an muscular influence) only the occlusion/occlusal contacts determine the position of the mandible, and thereby also the position of the joints are determined in the closed mouth situation.

Da osseointegrierte und osseofixierte Implantate (mit den daran hängenden prothetischen Konstruktionen) zur Hardware 1 gehören, muss die Art und Weise der Gestaltung der Okklusalflächen den Entwicklun-

gen des Knochens angepasst werden, und die Regeln der Zahnmedizin gelten nicht mehr. Damit ist es für uns möglich, eine vereinfachte Struktur der Okklusalflächen anzubringen. Tripodisierungen sind nicht mehr nötig. Sie sind vielmehr gefährlich, da einzelne Zähne nicht an ihrem Ort gehalten werden müssen. Und da der Durchbruch schon lange zurück liegt, müssen die Zähne über die Höcker also nicht mehr in eine sinnvolle Verzahnung geführt werden. Damit stellt sich die Frage, ob Höcker überhaupt noch nötig sind. Wir meinen, dass Höcker für implantatgetragene Arbeiten eher eine Mörser-Pistill-Funktion haben sollten. Dass sie dabei jedoch ausreichend Freiheiten für unterschiedliche Positionen und Angulationen des Unterkieferknochen relativ zum Oberkieferknochen ermöglichen müssen. Wir wissen, dass der unbezahnte Greisenunterkiefer den *Kieferwinkel* verliert, er entwickelt sich über die Jahrzehnte zu einem länglichen Gebilde, und es entsteht ein offener Biss. Dass Implantate diesen Vorgang verhindern oder verlangsamen werden, ist nicht bewiesen worden. Somit ist damit zu rechnen, dass fortwährend distal *Frühkontakte* entstehen, während der Unterkiefer seine Form langsam ändert. Genau dies beobachten wir während der langjährigen Kontrollen unserer Implantatpatienten.

Abrasionsformen von künstlichen Zähen wurden schon seit sehr vielen Jahrzehnten in der herausnehmbaren Totalprothetik benutzt. Sie ermöglichen das Zerkleinern der Nahrung, sie haben aber kaum Zentrierungsfunktion für die Zähne. Wir wissen aus dieser Erfahrung heraus, dass Höcker für die Zentrierung des Unterkiefers gar nicht nötig sind, diese Aufgabe kann dem **Weichgewebe 1** überlassen werden, ohne dass damit irgendwelche Nachteile für die Patienten oder das Resultat der Kaufunktion verbunden sind.

Joint Centric

In the relaxed situation and if no occlusal contacts or muscles being restricted by a hard-span are taking influence on the position of the mandible, if the malposition of the disc is not blocking full retrusion of the joints, the mandible will always strive to reach the “Joint Centric”” situation. The “Joint Centric” situation is influenced by the the morphology of the joints, the discs, the tendons and the muscles which hold the mandible.

In short: **Soft Tissues 1** determines the spatial position of the joint and the mandible. To some extent also **Soft Tissues 2** and **Soft Tissues 3** have influence on this position.

Only if unilateral contacts appear in the chewing zone, the mandible will strive for a more forward (mal-)position. This situation can occur at any time in life and for various reasons, and it can be easily corrected during control appointments.

Plane of Bite

In conventional dentistry the plane of bite does not play any role, because it cannot be changed in adults (except by invasive surgical means). Changes of the plane of bite are possible during growth and this option is used by functional orthodontic therapy. Only after at least one jaw is edentulous, we can think about changing the plane of bite while restoring this jaw. Often we are limited by the opposite jaw, especially if in this jaw elongations have happened.

Very often there are restrictions, especially if there are already elongations in one of the jaws.

In most areas of the world the Camper plane is used as a guideline for the plane of bite. I.e. most dentists emphasize that both levels should be more or less parallel. The reason is that for most individuals, this parallelism creates a situation in which both jaws close at a right angle. This means that the occlusal plane is hit by the cusps at a right angle in the final bite. If this is not the case, the lower jaw can slide uncontrollably forward or backwards. If we install the new bite, in many patients the lower jaw involuntarily moves back and forth until after some time the joint centric is habitually reached (see section 1.7.). For these patients it is important that the plane of bite is created in an identical manner on both sides. The stable situation at the jaw closure is of great advantage because the tripodization of cusp contacts is not required. Such "tripodizations" are the result of outdated mechanistic thinking, which should not be applied to the situation of hardware and the soft tissue. Today, "tripodization" is no longer carried out, although unfortunately the idea of tripodization is still found in countless textbooks on prosthetics. It is known that the soft tissues 1 to 3 guide the lower jaw of every person to very different "rest positions" during the course of each day. This fact alone indicates that the "tripodization" will only produce false forced bites during several periods of the day. Instead, today concepts like that of the AFMP and that of the APPI determine our work. The installation of a correct plane of chewing is vitally important for our work.

Mastication

Movement of the mandible against the stable maxilla, with the purpose of chewing food. During food processing there is close to no contact between Hardware 2 of lower and upper jaw, because constantly food is inter-positioned between the teeth. The occlusion plays no role for mastication as long as the occlusion centric is not laterally off the joint centric (see Fig. 2.1.). Protrusion, bruxism, speech function and constant control-movements of the lower jaw against the upper jaw are not part of "mastication". Disorders of the process of mastication requires no specific diagnostics. As for their therapy a standard dentition, with a bilateral pattern of mastication should be installed. The

tooth arches must provide equal AFMP & APPI, equal length usable of chewing surface left and right. The plane of bite should be close to parallel (or parallel) to the plane of Camper, and the frontal groups must be disengaged during occlusion and mastication. With these circumstances given, we can expect the self-normalisation of the process of mastication. However regular controls and slight corrections will be necessary to keep the situation stable.

Description of important pathways of co-ordination between the mentioned five components of neck and head (Fig. 1.1)

Soft Tissues 3 influence mainly the head position: A stable bite is created by a stable head position in the cranio-cervical joint (atlas-occipitalis). The head position changes throughout the day (J Prosthet Dent. 1992 Nov;68(5):780-3).

Hence the concept of "Tripodisation" is obsolete (outdated) and even potentially dangerous for constructions placed on immediately loaded dental implants. Tripodisation does not allow one to control forces, it rather leads to the development of an inappropriate intercuspidation (wrong bite/forced bite) during several phases of the day. In these phases a forced occlusal centric dominates over the joint centric. As teeth are not in contact during food processing, this aspect is especially important for tooth contacts during the rest of the day and it may trigger parafunctions.

Changes in the mandibular position generated by the **Soft tissues 1** lead to changes in the head position which was established by **Soft tissues 5**. They later compensate what **Soft tissues 1** "are doing" and vice versa. (Br J Oral Maxillofac Surg. 2017 Jun;55(5):471-475. doi: 10.1016/j.bjoms.2017.01.007. Epub 2017 Feb 28.).

If extra stability is required momentarily, the teeth are pressed together, e.g. during swallowing. Mainly in this moment, for the special task, the muscles around the hyoid bone become active. During swallowing Hardware 1 works together with Software 1, to allow the stable organization of the process. The pattern of swallowing changes with age (Exp Gerontol. 2019 Apr;118:45-50. doi: 10.1016/j.exger.2019.01.006. Epub 2019 Jan 8).

For the mandible position the TMJ is of minor importance. The muscles of Soft Tissue 1 are dominating this process. Patients with bilateral condylectomy can eat, which shows that the joints are not required. The same applies to patients with severe deformities/resorptions of the joints. Morphological changes as shown in Fig. 2.1.a and Fig. 2.1.b happen because the articular surfaces are able to change morphology

slowly and these changes are not connected to adaptation which bones are doing according to one of the Wolff`s Laws. Other bones at the end of our fingers and toes (basically under similar conditions of loading) do not have the possibility to undergo such changes (Fig. 1.2).

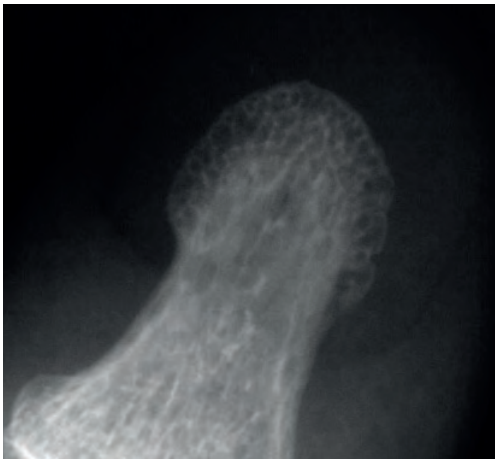

Fig. 1.2 *Radiograph of the tip of the finger. The outer circumferential cortical is maintained functionally (or at least modulated) by the finger nails, which create a counter-pressure while the fingers grab items.*

In addition to the interdependence of the five components described above, we find influences from the general skeleton and the associated muscle function. Those influences can be **permanent** (crippled patients, disabled patients with permanent malfunction of muscles, patients with otherwise deformed skeleton, patients with untreatable malpositioning of the shoulder-region, Fig. 6.6.a,), or **temporary** (patients with treatable function-derived localized muscle stiffness, patients with treatable "unequal leg length", patients with untreatable malpositioning of the shoulder-region, Fig. 6.6.a, etc.).

Altered function leads inevitably to a change in the distribution of minerals in the affected bone (Eur J Orthod. 2011 Apr;33(2):132-8. doi: 10.1093/ejo/cjq029. Epub 2010 Sep 30; Angle Orthod. 2005 Jul;75(4):625-30; Am J Orthod Dentofacial Orthop. 2005 Dec;128(6):766-73.) Therefore, for example, Angle Class 2 patients provide a different pattern of the bone's mineralization compared to Angle Class 1 cases. Due to their anterior pattern of chewing, their inability to perform effective lateral chewing and the elongation of the upper and lower front teeth the distribution of the bone in the mandible changes as well as the pattern of mineralisation. More and more mineralized bone appears around the front teeth, while especially in the distal mandible less bone is found. Hence these patients have a higher chance of developing bone atrophy (even while they have teeth in the distal mandible), and this atrophy finds manifestation in profound periodontal-disease and open bifurcations. If the functional pattern is not changed (e.g. through a comprehensive treatment concept) they will later develop peri-implantitis (around their 2-stage implants) for the same reason.

The No-Front-Contacts Concept

It is for many dentists not easy to recognize the enormous advantage of the rules which are laid down in this booklet and which are better obeyed in the immediate functional loading protocol. Especially important is the "no-front-contacts-rule". Dentists learn in their education that full dentures should not have front contacts (neither in occlusion nor in mastication), but in most countries their education does not lead to a full understanding of the effects of this step and the advantages of this strategy. They say: "Anyway its the job of the dental technician to know what a full denture should look like and how it works".

In addition most dentists tend to have their own teeth with the front teeth being in contact one way or another. Hence they believe that "this is normal", and that it is the only way. There is definitely a need to explain in detail here which excellent other option we have to create defined and controllable occlusion and mastication.

From soft tissue based full dentures we can learn a lot for the concept of immediate functional loading. One very effective way to make a full denture unusable is to create static contacts between the upper and the lower front. The reason is that the denture will be moved out of its position with every movement of the lower jaw and even by a simple closure of the mouth. As soon as we raise the bite and free the fronts, static forces are going to act vertically and when closing the mouth the dentures will be pressed vertically onto the teguments in the lower and upper jaw.

We know from the lessons about bone physiology, the pressure in general increases the mineralisation of bone, while tension leads to osteoporosis. Unfortunately we all have learned from the field of removable dentures, that "denture pressure leads to atrophy", and this potentially misleads our thinking dramatically. It is true that the jaw bones atrophy under dentures, but the pressure is not the reason. (We know for example, that the size of the denture base in the lower jaw is not correlated to the amount of atrophy.)

Hence we have to make sure that our implants will be as little as possible subject bone to tensile forces, - i.e. extrusive forces. Would we bring the frontal groups into occlusal contact, we would be unable to control extrusive forces on the most distal implant in both jaws. While this is usually not a problem in the lower jaw, it can become a big problem in the upper jaw and the most distal implants could become mobile. The No-Front-Contacts concept has strong implications on the demand which we must have on the plane of occlusion. Details are explained in Chapter 1.8.

1.3. Necessary Chewing Surfaces

Chewing surfaces with a total length of three premolars are sufficient for an equal bilateral mastication. This concept can be realized easily in Cases of Angle Class I, Class II, and Class III. For Angle Class I and Class II patients we install two premolars and utilize the anterior part of the first molar for chewing. We use the upper canines for chewing (Premolar-shaped teeth replace the upper canines, in order to place another tooth with the possibility to actually chew) only in Angle Class III cases.

1.4. Surfaces of the Hardware 2 which should never be in contact with the opposing dentition.

We consider all contacts on 2nd and 3rd molars as undesirable, they are early contacts. They represent potentially dangerous early contacts that must be avoided from the beginning.Not that all contacts which are considered occlusal contacts must be located on horizontal areas of the crown or bridge, and not on cusp slopes. The principle of tripodization (at least 3-point contact for each individual tooth) may be applicable to the design occlusion of single crowns and bridges. And it may be useful for learning a theoretically possible type of occlusion. In clinical reality, tripodization is more likely to be harmful in the dentulous jaw. Therefore, tripodization must be considered as a quite useless “human invention”, and thanks to abrasion this kind of construct is (luckily) abraded away soon if the materials used allow this.

Angle Class I

We consider it the optimum if the skeletal situation allows restoration in an Angle Class I molar relationship. As Strategic Implants may be placed in a different position later than the teeth, this concept is applicable in many cases where a slight Class II or Class III was given pre-operatively.

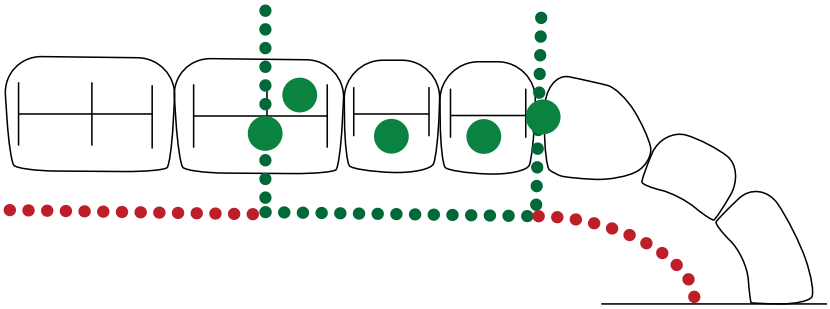

Fig. 1.3a *Upper jaw, full bridges. For regular function teeth in the length of 3 premolars are sufficient. It is recommended to avoid all contacts on the 2nd molar, the distal 1st molar, and between the cusps of the two canines. 3-4 occlusal contacts are enough for normal mastication. This graph shows the upper jaw dentition in a typical Angle Class I jaw relationship. Another occlusal contact in the centre of the first molar near the green dotted line is a good option. Contacts on the canines or anterior part of the 1st upper premolar are only an option for circular bridges. See* ***Fig. 1.3b*** *for segments.*

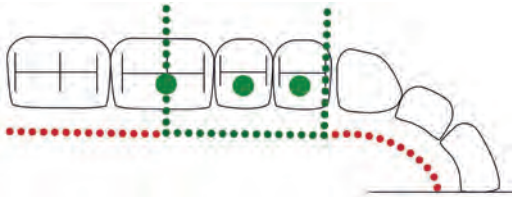

Fig. 1.3b *Upper jaw. In segments the supporting polygon is severely reduced and contacts on the anterior part of the 1st premolar are typically outside of the polygon created by the implants (unless the anterior implant reaches the floor of the nose through a canine bypass). The installation of a lingualized occlusion is recommended. The upper vestibular cusps of 1st molar and the premolars are never in contact with their antagonists.*

Angle Class II

Especially in skeletal Class II situations this concept will lead to a full disengagement of the upper and lower front teeth. This will **not** trigger elongations[1], however it may lead to an altered sagittal mandible position.

---

1 We have all learned during our studies that teeth must be in occlusal contact lest they elongate. In reality this assumption is not true in all cases. In order to trigger elongation two conditions must be given: The segment in which the tooth is positioned must be activated by functional contacts AND the 2nd tooth must be without antagonistic contact. Without this activation of a functional segment, a tooth without contact is more likely to intrude, thereby following bone's atrophy.

Note that for this consideration the mandible consists of 2 segments while the maxilla consists of 3 segments:

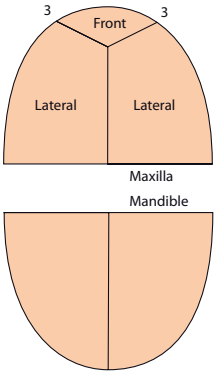

Fig. E1 Functional division of the mandible and the maxilla regarding possible elongations of teeth:
Example 1: If (predominant) function is on teeth 22, 23 the whole frontal segment in the upper jaw is activated. 22, 23 will probably be intruded by function and dislocated to the lateral/front (with gaps developing between these teeth), while 11, 12, 13 will tend to extrude (with signs of crowding appearing between these teeth).
Example 2: If in an upper lateral segment the tooth 14 is left and in function (with teeth 15, 16, 18 missing), tooth 17 will tend to elongate if no antagonist prevents this.
Example 3: If in an upper lateral segment the tooth 14 is left and NOT in function (with teeth 15, 16, 18 missing), tooth 17 will tend to lose contact to the antagonist and dislocate cranially.
Example 4: If one lower front tooth is functionally activated all lower teeth on the same side tend to elongate if antagonists are missing.
Example 5: If all lower front teeth are activated, all lower teeth tend to elongate wherever the antagonist is missing.
Notes:

1. If a tooth elongates under the rules which are explained here, then it stays elongated, even if the teeth which have functionally activated this tooth (segment) are later removed. Because of this, we often find clinical situations where it seems to us that the rules did not apply.
2. Note that conventional implants create a remodelling in the whole jaw. At the end of the remodelling less bone is present, compared to before. This way implant-borne prosthetics can easily lose the functional contact to the opposite jaws dentition. We see this development frequently as soon as we understand the reason behind it. The typical countermeasure is to renew the prosthetic workpieces or to lift the bite on them (e.g. if the prosthetic workpiece is made from composite or acrylics. We assume today, that prosthetics which are anchored in the 2nd or 3rd cortical show a smaller tendency for such a loss of vertical, compared to implant-borne constructions which are osseointegrated in the area of the 1st cortical.
3. Chewing forces have a strong influence on the vertical position of the teeth. If chewing forces are higher on one side compared to the other side, then intrusion has to be expected on the chewing side, whereas elongations and crowding will be seen on the non-chewing side (as a result of disuse atrophy).
4. It must be mentioned here, that the hormonal status of the patient (his or her age) are also influencing the developments, because atrophie may happen inside the bone (i.e. osteoporosis-like, Jaworski et al., 1980) or from the outside (Uthoff & Jaworski 1978).

Very often Class II patients habitually protrude the mandible for anterior chewing and anterior rest position. They may find the way back into the dorsal (centric) condyle position when sitting in the dental chair, but the vast majority will not stay and function with the mandible remaining in a distal position from then on.

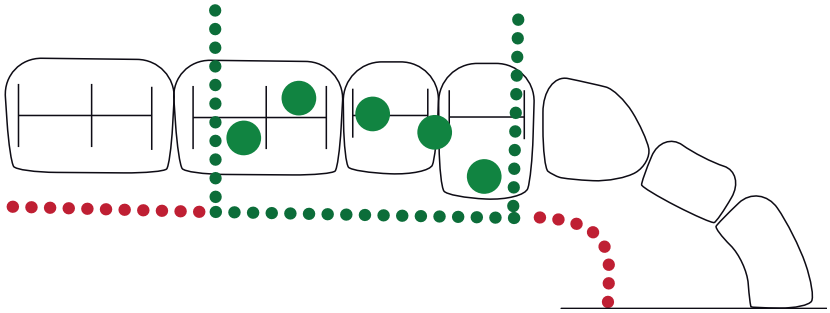

Fig. 1.4a *Upper jaw. If the mandible is retracted it will be impossible to create contacts on the 1st upper premolar, except if this tooth is created wider towards the palate. Note that this increase in width may conflict with the necessary freedom for the tongue movement (see below Chapter 6). The anterior red dotted lines indicate that there will be a considerable step between the upper and lower dentition.*

Fig. 1.4b *Insertion of lateral bridges in an Angle Class II patient. The joints are in Joint Centric. No frontal contacts are given in this position, (aslo) because the bite has been lifted.*

Fig. 1.4c *24 hours after incorporating the bridges the patient had moved the mandible a bit out of the dorsal (centric) joint position into a more anterior position. This required a slight adjustment of the occlusal situation and the mastication and at the same time it indicates that the bite was probably not lifted enough. The correct and stable position of the mandible may frequently not be determined in Class II patients, see Fig. 2.1 b and consider the explanations given there. The patient will figure out the best mandibular position for himself. See also Fig. 1.19c.*

Fig. 1.4d *Full upper jaw restoration and lower segment restoration. The lower front remained unextracted. Skeletal Angle Class 2. The upper teeth are in the same position as the patient's teeth. After this the vertical dimension is adjusted (raised) to the standard, the front teeth are out of contact and they will remain like this.*

Fig. 1.4e *The same case from a different perspective. Note that the upper arch tends to be wider than the lower arch, which can create difficulties in arranging contacts for the upper 1st premolar. This denture-tooth must be designed wider towards the palatal direction to get in contact with the lower antagonist. This contact of the 1st premolar is very important for a functional mastication. Upper and lower front teeth are designed in a length that enables taking a bite of an apple in any possible case.*

It is sometimes argued that frontal contacts are natural and compulsory for humans. We cannot confirm this. We would like to remind the readers that full dentures are never construced with frontal contacts, as they would become unstable with such a configuration. Nevertheless patients can eat with well constructed dentures without any problems as long as the intraoral anatomy (or implants) permit to fixate them suffciently.

The fact that in Angle Class 2 dentitions the frontal groups seek (almost desperately) contact to each other should not misslead our thinking: the frontal contact is achieved only with the help of a massive non-natural deformation (actually an elongation with the bone) in the upper and the lower jaw. Consequently dental medicine named the Kelly-Syndrom a „Syndrom“ and just as the „Angle Class 2 syndrom“ it consists out of functional and anatomical components. The Kelly syndrom can be considered as a special case of bone deformation, and it must be subsummarized in the same category in which Angle Class 2-deformations are also listed.

In literature we see that human „mastication“ was descibed in many details over centuries. Maybe due to so many details the overview got lost in our profession. We have to accept (not neglecting the many details however) that a large variety of functional movements lead to successful and carefree mastication. Humans can chew for decades with an anterior pattern of chewing, while others use a lateral pattern of chewing successfully - also for decades. Both groups eat and „masticate“, but the group members actually do something completely different! Persons with frontal contacts during occlusion tend to develop anterior patterns of chewing and their lateral movements are often categorized as to have „frontal guidance“ or „canine guidance“. Patients without frontal contacts are able to chew lateraly. Abraded and eroded teeth can blurr the borders between those two patterns of chewing. None of of these functional variants can be considered superior (Abduo and Tennant, The Journal of Prosthetic Dentistry, 2015 , Volume 114 Issue 2 , 193 ff). From these patients we can also learn that neither cusps nor a Spee-curve are required to masticate happily and successfully throughout life. If we move patients from an anterior pattern of chewing to a lateral pattern of chewing, it will take some seconds for the patient to adapt. About 35% of our patients make (negative or doubtful) comments about the fact that there are no frontal contacts after the incoporation of bridges. Months or years later 100% of the patients will confirm however that they have frontal contacts just as normal (although they still dont have them of course).

From all this we can learn that the human masticatory system may cope with all kinds of changes throughout our life (tooth loss is not considerd here), and it does this with the help of the adaptability of „Software 1“ (Fig. 1.1).

Angle Class III

If it is necessary to diagnose the skeletal situation pre-operatively or post-operatively, a lateral radiograph may be taken. Both the ANB angle and the Wits appraisal should be considered for the diagnosis, i.e. for measuring the true discrepancy between the mandible and the maxilla[2].

In Angle Class 3 cases the upper canine must be adjusted in morphology to serve as a 3rd premolar, this tooth will therefore need an occlusal surface.

Note that the situation in Angle Class III patients may often be improved significantly by a slight increase of the vertical dimension. Such an increase in the vertical will reduce the ANB angle. According to our experience sagittal discrepancies up to about 3.5 cm can be treated with Strategic Implants. In such cases the front teeth may have to be positioned in an edge-to-edge contact situation or even in a slight cross-bite.

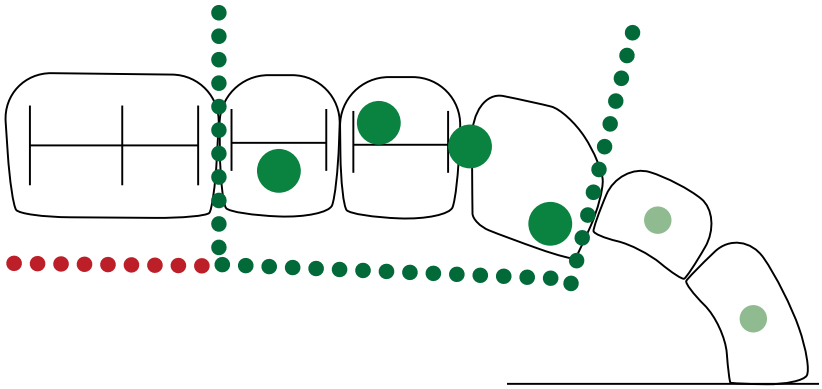

Fig. 1.5a *Upper jaw. In an Angle Class III situation the upper canine must function like a premolar, and in most cases contacts on the upper 1st molar are not possible. If we create front contacts, they will require meticulous occlusal adjustment because these contacts are all outside the supporting polygon. Some slight edge to edge contacts are allowed to appear on the "occlusal surfaces" of the anterior upper teeth (light green points), however full occlusion or even early contacts in this area are not allowed.*

Note that in Angle Class III patients we don't have to fear an advance into the lower jaw for mastication. These patients provide a TMJ with a predominant hinge-function and almost anterior translation down the processus articularis.

2 With the help of the Wits appraisal (analysis) we evaluate the rotation of the maxillo-mandibular complex vs. the cranio-facial complex. High ANB values indicate a severe (i.e real) discrepancy between lower and upper jaw if the Wits value is high. Recently the W-angle was described, and this tool may be used for diagnosis if upper molars are present). Both Wits-appraisal and W-Angle serve to overcome the limitations of the ANB-measurement to some extent. (Pervez H., Ahmed I., Int. J. Dent Health Sci 2014; 1(3): 299-304)

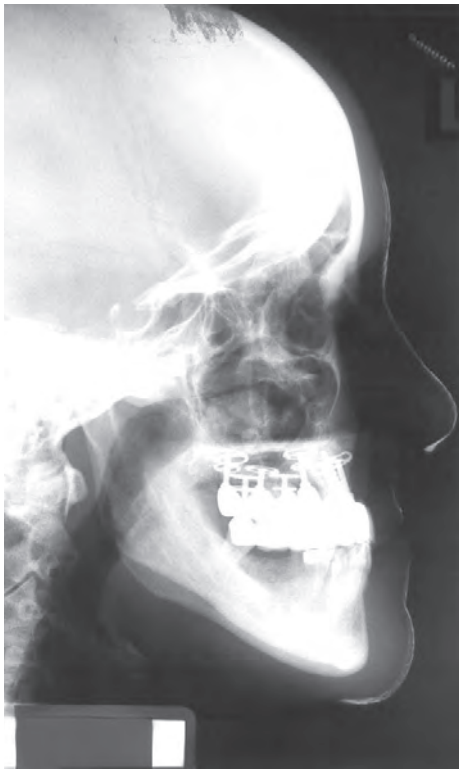

Fig. 1.5b *Pre-operative lateral radiograph and post-treatment radiograph of a Class III case treated with BOI implants only. The anterior cross-bite was corrected by the bridge. Large distal base plates were necessary to encounter distal extrusion forces. This case was treated 1997 and it was well in function at the time of the publication of this booklet. Today we would rather use screwable basal implants and anchorage in the tubero-pterygoid region in order to avoid the quite invasive surgery which is necessary for lateral basal implants.*

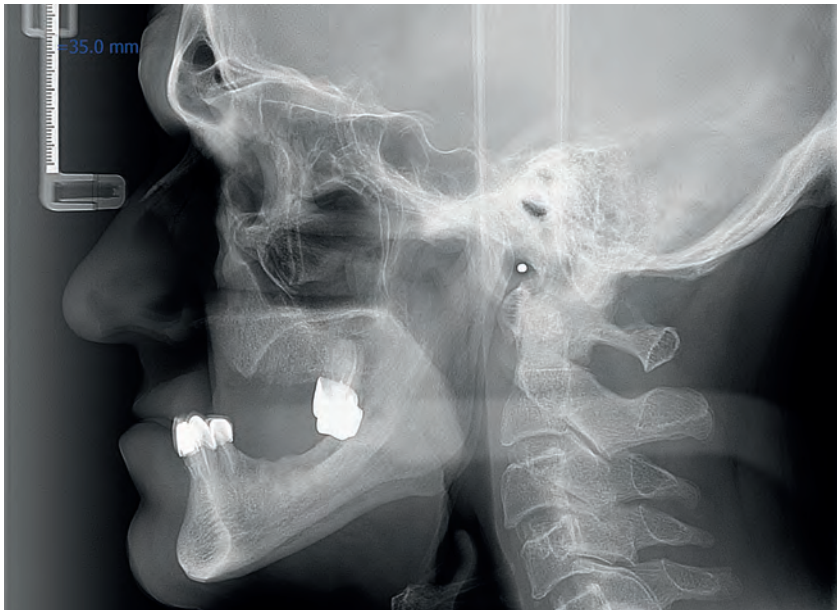

Fig. 1.5c *Pre-operative lateral radiograph showing a large sagittal step. According to our experience a sagittal discrepancy up to 3.5. cm can be overcome with the help of Strategic Implants.*

Fig. 1.6a *In severe Angle Class III cases only the upper canine and the premolars can be brought into contact with the lower dentition. If the upper canine is formed like a premolar, the patient will have a total of three premolars for chewing, which is usually enough. Neither in Angle Class 1, nor in Class 2 or in Class 3 frontal contacts are necessary (nor desirable) in occlusion.*

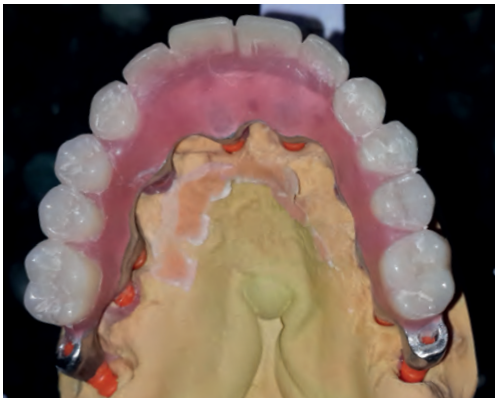

Fig. 1.6b *In less severe cases the canines in the upper jaw functionally work as premolars. They contribute to the chewing function.*

Fig. 1.6c *Because the upper front teeth are not supported by implants, frontal contacts must be avoided or minimized. One additional lower molar may increase the ability to eat, however their presence is not essential for the stability of the construction.*

Fig. 1.6d *The upper jaw bridge already includes a 1st molar in the correct position.*

When treating Angle Class II and Class III cases to reach the Class I standard, avoiding the placement of implants between the canines is a good strategy as it makes the life of the dental technician easy and promotes aesthetics. In any case the concept of the "supporting polygon" does not require implants in these locations.

1.5. A Sufficient Vertical Dimension Allows "Mechanical Harmony"

Choosing a sufficiently high enough vertical dimension is critical:

- If the vertical dimension is not high enough it will be difficult or even impossible to disengage the frontal teeth in occlusion and during mastication
- During the years of usage of implant borne bridge it will be repeatedly necessary to grind the occlusal contacts, masticatory slopes, or both. This will further reduce the vertical dimension.
- Only a sufficient vertical dimension will lead to a correct head position on the spine, and prevent damages and pain in the spine and muscles keeping the upright position.
- Only in a sufficiently high vertical dimension patients reach the dorsal joint centric at all. Both the increase of the vertical dimension to the standard, and reaching the joint centric will often lead to a loss of front contacts. In other words: more patients than we think are in reality "constructed in an Angle Class II" jaw relationship or have developed towards it.

- Because Angle Class II patients are in an unfortunate skeletal situation from the start, they tend to lose their teeth earlier and the percentage of Class II patients which become our customers (i.e. requiring implants) is highest compared to Class 1 and Class 3.
- Note that front-contacts are not required at all for maintaining oral health and a well functioning mastication

If we start off with a vertical dimension that is low or even too low, we will soon end up in a situation where we can prevent contacts in the frontal group only if we reduce these teeth vertically. This often leads to bad aesthetics. If these teeth are natural, it will lead to discussions with the patients, subsequent hyper-sensitivity, and eventually to root canal treatments. Hence we recommend choosing a sufficiently large, natural vertical dimension at the onset of the reconstructive treatment. The adjustment is done in one step, regardless of how much the bite must be lifted.

Also keep in mind that our bones and muscles have been developed and designed for the "original" vertical dimension. Although this height may have been lost over the years, it is always considered correct to bring the vertical back to normal in one step. This allows the masticatory apparatus to function in "**mechanical harmony**".

Although occlusal and regular masticatory contacts in the frontal group must be avoided, we have to create the tooth arch in such a way that the patient can take a bite from an apple. During this movement the premolars and molars must not be in contact.

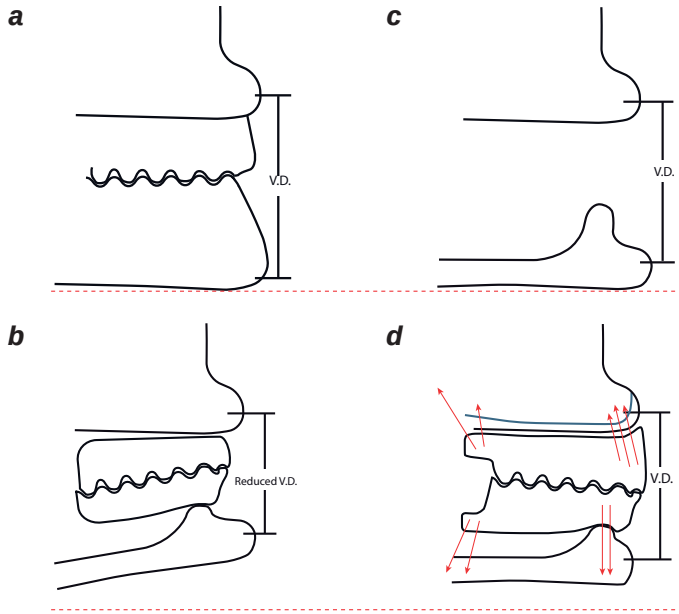

Fig 1.7a-d
a *Upper and lower jaw with normal vertical dimension V.D.*
c *Edentulous jaw with normal vertical dimension. V.D.*
b *When using the conventional implants this vertical dimension cannot be restored due to the rule about the relationship between the length of implant bodies and the crown length. This leads to too small prosthetic workpieces, which is why the bite is automatically lowered. This has considerable biomechanical disadvantages.*
d *Since the technology of the Strategic Implant® does not apply the length ratio between the endosseous part of the implant and the crown length, the normal vertical dimension can be restored. This automatically creates normal mastication In the case of skeletal class 2 patients. In this group of patients the anterior teeth in upper and lower jaw are also no longer in contact and this is extremely beneficial for adjusting the chewing function.*

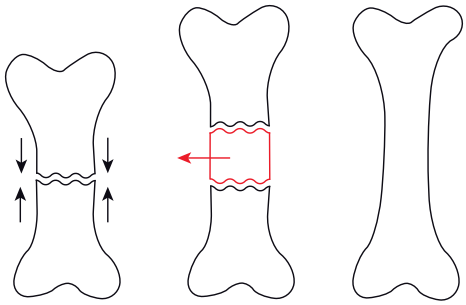

Fig. 1.8a *When long bones are fractured, the treatment will always be performed in the direction of re-establishing the original length of the bone! It makes no sense to remove a segment of bone or reduce its height (as shown in this figure) since all other components of the musculo-skeletal system (especially the joints) require the longstanding spatial relationship between muscle and bone - as developed at the end of the growth phase - for functioning mechanical harmony. In our field especially a sufficiently high vertical dimension is required. No traumatologist would do what is shown in this picture. Only we dentists seem to be thoughtless enough (or helpless) to create our work in a reduced vertical dimension: this is what we see often during the clinical observations of users. A good overall treatment plan in cases where tooth-segments are left in demands often several corrections in these segments. Small mistakes which have been accumulating in a dentition over decades must be corrected to bring function to the standard. If the surgical and prosthetic treatments are done by different treatment providers, a good common plan must be set up before treatment starts. We therefore recommend, especially when reconstructing only one jaw or part of the jaw, to carry out the two work parts (surgery and prosthetics) in* ***one*** *practice/clinic to allow close co-operation between the disciplines.*

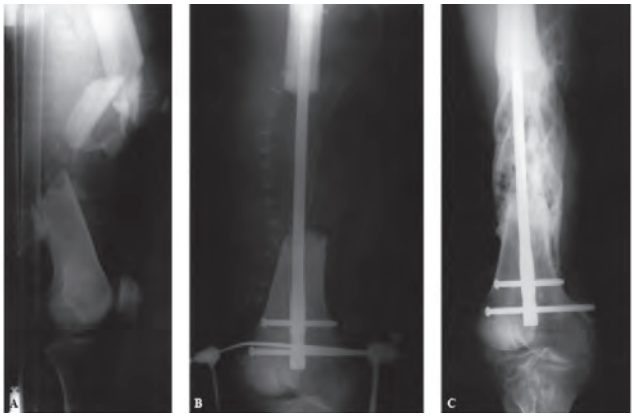

Fig. 1.8b *Femoral fracture (A) treated with an intra-medullary nail (B). New bone formation (C) stems from the periosteum only. An augmentation is not required. We show this picture in this book and ask crestal implantologists to consider it whenever they think that treatment is not possible without bone augmentation. (From: Andreas F. Hinsche et al 2003 : Spontaneous Healing of Large Femoral Cortical Bone Defects).*

When treating fully edentulous patients it is easy to restore the vertical dimension to the standard. Changing (i.e. increasing) the vertical in all other cases requires crowning at least one jaw completely. If the roots are short in comparison to the crown, this procedure is not an option since the unfavourable relationship between root length and crown height may lead to cantilever derived mobility of teeth and subsequently tooth loss.

Note also that it is difficult or impossible to disengage the frontal group of teeth (3-3) in occlusion and mastication if the vertical dimension is too low. When lifting the bite, the mandible will automatically retract. This leaves more sagittal space between the upper and lower frontal dentition and this is what we need for treatment protocols in immediate loading!

The installation of an increased vertical dimension (to avoid front contacts) with a natural front dentition being still in, is possible only to a very small extent. This treatment step should be considered only

- if the upper and lower front teeth (and possibly other teeth) are extremely abraded, and if
- this loss of vertical height was not compensated by the simultaneous elongation of these teeth, and if
- the front dentition is healthy from periodontal point of view.

As a rule, the anterior teeth in the areas of the jaw affected by the abrasion are then promptly supplied with crowns, which gives them their initial height again. It must be ensured that the occlusal plane remains parallel to the camper plane or is adjusted correctly, even if the lengths of the upper and lower crowns may not be ideal from aesthetic points of view.

These patients have very high chewing forces and parafunctions, which have to be reduced by administering botulinum toxin to the masseter muscle for at least a few months in the context of implant therapy (in immediate loading). The effect of such an intra-muscular administration of botulinum toxin lasts for an average of 2 months, and repetition of therapy must be considered. Although botulinum toxin works equally well in all striated muscles, treatment of botulinum toxin masseurs in some countries is off-label use and must be considered critically on a case-by-case basis.

The free re-adjustment of the vertical dimension according to standard parameters will not work well in cases where patients still have sufficient lateral occlusion contacts on their own teeth. The extension of teeth by higher crowns is a risk in terms of stability of the teeth. In addition, in these patients is not to expect a displacement of the lower jaw anterior.

In some cases we have to raise the vertical dimension (compared to the onset of the treatment) 1 cm or more. This will lead to a dramatic change in the optical appearance of the patient. Some patients will not accept this initially, as they are not used to showing teeth so prominently. Such changes in the appearance may also lead to a changed (upgraded) social position. Keep in mind that other people in the vicinity of our patients might not accept an improved appearance or social position, and they will subsequently start boycotting the results of our work by advising the patient wrongly. This can severely interrupt the trustful relationship between patients and the treatment provider.

1.6. The AFMP concept

The "AFMP"-angle (Angle Fonctionelle de Mastication de Planas), <u>must</u> be identical on both sides at the end of the prosthetic treatment and this functional symmetry (but not the angle itself!) must be maintained throughout life.

Whenever this angle is not identical, the patient will quickly develop a unilateral pattern of chewing on the side with the more shallow angle. We need to adjust this angle by adjusting the length and the slope of the buccal cusps in the upper and the lower jaw.

It does not matter how steep this angle is as long as the angle is the same on both sides. In the natural (and especially the untreated) dentition, this angle changes throughout lifetime: the angle is shallow in newborn children, it increases with the eruption of the first dentition and becomes steeper yet when the second dentition appears. The steepness can be the result of anterior or posterior guidance. Later in life the angle returns to a more shallow state as abrasion shortens the cusps. In patients with multiple metal-to-ceramic crowns and similar restorations, the angle cannot change any further due to lacking natural abrasion. Therefore we have to adjust the angle in these patients during routine controls.

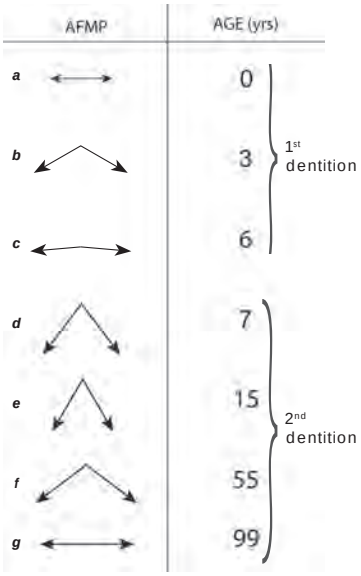

Fig. 1.9a-g *New born babies have no teeth and their AFMP is hence 180 degrees. The AFMP becomes steeper, as soon as deciduous teeth appear. The first set of teeth shows fast abrasion and this partly compensates spatial changes caused by fast growth. This growth does not allow a permanent intercuspidation. At the end of the usage period of the deciduous teeth, the AFMP of a 6 year old child without 1st molars is almost 180 degrees again.*

As soon as the permanent teeth appear (age 7-12), they grow into a reliable, permanent inter-cuspidation and the AFMP gets steep again. Due to natural attrition the AFMP then flattens over years and it can reach again 180 degrees.

This (among other considerations) demands that we grind away buccal cusps of the upper lateral dentition throughout life, especially in teeth with metal, metal-ceramic or zirconium restorations. Unadjusted these restorations will sooner or later start to block the function.

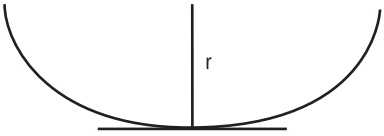

Fig. 1.9h *If cuspless (prosthesis-) teeth (so-called "abrasion shapes") are placed on a spherical "Kalotte", the AFMP can even become negative. Even laterotrusion no longer leads to the mouth opening, but only to a slight shift to the side. Unfortunately, in the age of "gnathology", this simple and always functioning principle of mastication was completely forgotten and the dental profession has instead dealt with the questions of the "tripodization" of occlusion contacts, which is almost always inoperative. The radius "r" of the sphere is connected to the Angle Class.*

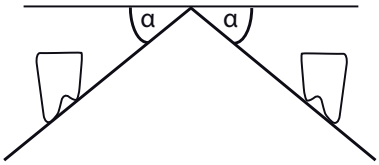

Fig. 1.10a *Example of a steep but bilateral identical AFMP.*

Fig. 1.10b *Rather flat AFMP due to the fact that the vestibular cusps of the upper dentition are not very pronounced. This type of cusp is recommended for immediately loaded implants.*

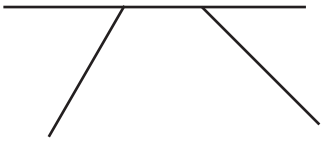

Fig. 1.11a *Separate occlusal centrics ("two bites") may show such a graph. Often neither of the two occlusal centrics is identical with the joint centric. Such conditions can be created through overly wide rapid palatal expansion during an orthodontic treatment, if the mandibular arch remains too small. Patient can bring the mandible to good occlusion either on the right side or on the left side, but not in both sides at the same time.*

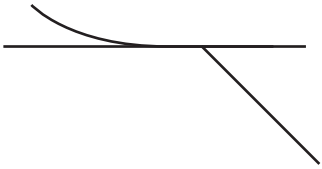

Fig. 1.11b *This drawing shows the picture of the AFMP on a patient with cuspless mastication along a (theoretical) callot (pt. right side), whereas on pt. left side a regular AFMP is recorded.*

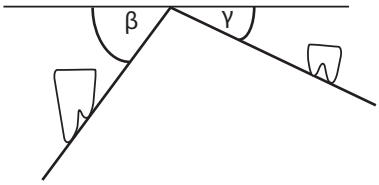

Fig. 1.12a *Example of non-identical AFMP. This patient will predominantly chew on his left side (Gamma Angle). The other side (with larger Beta Angle) will be avoided because it is too much effort to open the jaw for chewing to take place on this side. Such a situation will lead to overloading of immediately loaded implants on the chewing-side, while the non-chewing-side will become a tension. This likewise leads to implant mobility: however, the reason is demineralization due to tension (tension-osteoporosis).*

Fig. 1.12b *Cusps are not required for successful mastication. This example shows how two jaws are restored with metal-plastic-bridges featuring an absolute minimum of cusps and AFMP-deviation. Fissures in the molars and premolars are enough to support the process of bolus pressing. The TM-joints alone will centre the lower jaw and fix its position in relationship to the upper arch.*
Make sure that the 2nd molars are not in any contact relationship.

In general we recommend creating the AFMP as flat as possible, i.e. to create upper premolars and molars almost without cusps. This way lateral forces are small during mastication. Cusps are mainly required during the eruption of teeth to direct them into occlusion and the correct spatial position. Cusps do not increase the success of the chewing activity. Food is also crunched well between flat tooth surfaces after the masticatory function has adjusted to the situation. An acceptable AFMP angle at the onset of treatment will lie between age 55 and age 99 (see Fig. 1.9) and during control appointments the AFMP will become progressively more shallow.

1.6.1. Three rules of Dr. Pedro Planas

The Spanish dentist Dr. Pedro Planas established in the last century three main rules by which he describes the contact situation and the functional situation between upper and lower jaw, as well as the pattern of functioning. We have modified and explained these rules as follows:

a. Rule of the minimal vertical dimension

Originally the rule states, that a patient moves the mandible anteriorly, if he/she can thereby close the mouth more (i.e. reduce the vertical dimension). Today we define the reason for the development of a "long centric" movement differently:

A patient closes the mouth to reach equal bilateral contact

or

advances or deviates the mandible until bilateral equal contact is reached,

or

until front contact is reached.

The patient prefers the most distal rest position of the mandible in which bilateral equal contact is possible.

b. The rule of the AFMP (see Fig. 1.9) and other factors influencing the pattern of function:

A patient will develop a unilateral pattern of chewing (preferred chewing side), if the AFMP is unequal on the both sides.

The patient will develop a unilateral pattern of chewing (preferred chewing side), if on one side of the mouth more functioning chewing units are present than on the other side.

The patient will develop a unilateral pattern of chewing (preferred chewing side), if the chewing surfaces are on one side significantly wider than on the other side or if the sum of occlusal contacts is much larger than on the other side.

The patient tends to develop an anterior pattern of chewing or a functional pattern which is overly guided by frontal mastication,

if the frontal group touches either in occlusion or during mastication

or

if the AFMP is overly steep.

c. The masticatory function leads to an adaptation of the morphology of

- the temporo-mandibular joint
- the bone`s morphology
- the tooth position
- the occlusal plane in each function segment of the jaws (see Fig. E1)

1.6.2. Considerations regarding the AFMP and lateral crossbites

In general we recommend to create in any case a symmetrical tooth arch, regardless of the atrophy and the eventual deformations of the jaw bones. The lower 1st molar should in any case be in its best (former) spatial position, regardless of the position of the distal implants. In cases of strong atrophy there will be no bone below the 1st lower molar. This seems initially unusual, and most astonishing is that patients with such a construction – with the 1st molar as last tooth on the bridge being so much medial – can masticate and speak without any problem, so long as we are creating a symmetrical situation.

Fig. 1.13a *This metal frame shows an ideal design with good support of the tooth arch and technical abutments which are more vestibular. The implants were placed according to the bone supply much more vestibular than the frame can possibly be. Would the dental technician connect all implants with a straight line of metal, the lower 1st molar would be automatically in crossbite and the upper tooth arch would be positioned (too) far outside of its supporting polygon.*

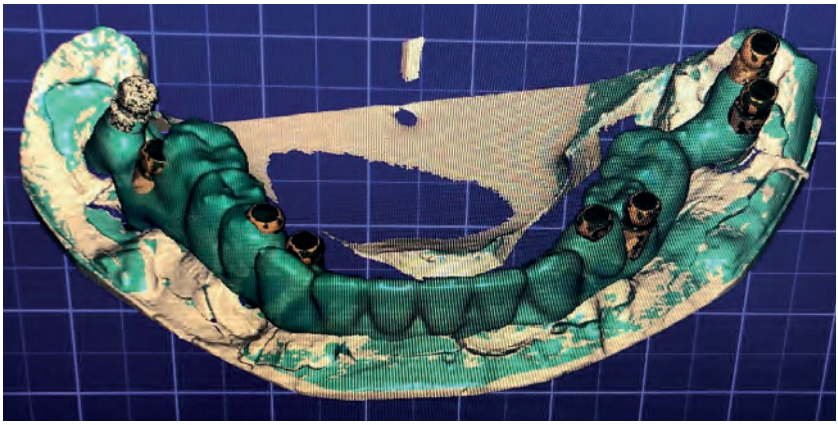

Fig. 1.13b *shows an ideal lower jaw arch during digital construction and more vestibular the distal technical abutments.*

If such compensation as shown in *Fig. 1.13a* is not possible, the 2nd best solution is a bilateral crossbite.

A unilateral crossbite is in any case no option (neither for segments nor for circular bridges), because the AFMP can never be symmetrical under such circumstances. If the AFMP is different (left/right) a unilateral pattern of chewing will develop and this will often lead to osteolysis, it may be overload-osteolysis or disuse-osteolysis (in tension zones).

1.7. The APPI Concept

The **AFMP**-Concept (**A**ngle **F**onctionelle de **M**astication de **P**lanas, see chapter 1.6) describes the disclusion of both jaws during lateral movements of the mandible. It was shown in Chapter 1.7. that vestibular upper cusps are guiding this process for the natural dentition and if traditional teeth according to Fig. 5.3 2b, A are used. Other variants of this process of disclusion are described in the Fig. 5.3 2b, B and C.

The **APPI**–Concept (**A**nterior-**P**osterior **P**lanes by **I**hde) describes the possible disclusion during anterior and posterior movements of the mandible while the lower occlusal surfaces are under (at least momentary) contact with the upper dentition. In fact the APPI concept describes a feedback slope and we will now look at the matter and at its implications on our daily work. According to this concept the contacts and the APPI during prostrusion and retrusion is dominated by the Hardware 2 and not by the condylar path. The idea of the "condylar path" and its angle were born when articulators were invented. Unfortunately this idea has fundamental flaws: simply by looking at the shape of the TMJ´s and their angle to each other makes it clear, that at least in anterior movements the involved surfaces cannot be in guiding contact and that the movement must be principally steered by muscles.

1.7.1. Description

As pointed out in chapter 1.2. we design our bridges in a way that frontal contacts in occlusion and mastication are strictly avoided. Frontal contacts are only reached during protrusion and e.g when the patient is biting off an apple. Whenever bilateral and simultaneous posterior contact cannot be established, the mandible will move anteriorly to find such contacts or at least to establish (finally) contact between anterior teeth.

The down-side of this concept is that our patient will not get an immediate full disclusion of the dentition (of the upper and lower jaw) during mastication (and especially during protrusion), because the lower front cannot slip down on the palatal side of the upper front teeth. This process would cause such an immediate disclusion of the (posterior) chewing surfaces. When this movement occurs in the neutral dentition, a tripod is created. It consists of the two joints and the anterior contact.

After many years of supervising patients who received full rehabilitation and had no frontal contacts (not in occlusion, not during mastication, but they had contacts during protrusion), we can conclude safely that humans do not need frontal contacts at all during centric occlusion and during masticaton. Hence the concept which is utilized for full dentures may be applied for our work also.

The temporo-mandibular joint performs (other than the typical articulator) only translatory movements.

The ideal plane of bite is parallel to the plane of Camper. If the APPI is parallel to Camper and identical on both sides, the individual can masticate well and there are no principal blockages.

If however the APPI happens to be under an angle to the APPI of the other side of the same patient, either the protrusion or the retrusion is slightly blocked and this can only be overcome by an unilateral open bite during the functional movements.

If the APPI is different on both side, patients have difficulties to determine on which side of the (new) construction is the first contact. The reason is that even a slight retrusion of the mandible (in the direction of the joint centric) will lead to an unilateral contact, and unilateral occlusal contacts are answered (in a reflex) by the masticatory system with a slight protrusion of the mandible. For the brain and the functional steering an unsolvable problem is generated if APPI is different on the two sides. Of course we can in many cases solve the problem by massive grinding in both jaws in order to create equal APPI. But this grinding costs vertical and it leads often to new problems. It will also not make a good impression to our patients if we start grinding a lot at the end of the treatment, instead of instructing our technicians well or starting from the beginning with a complete treatment plan.

It is important to make sure that the APPI is identical on both sides and we better understand what needs to be done in non treated areas of the jaw, e.g. in segment cases and in single-jaw cases. The treatment involves changes in the opposite (untreated) jaw as the following case study shows, but it also requires meticulous work of the dental technician and a proper planing of the APPI.

It has to be mentiond here that a relapse of the TMJ can happen at any time during or after the treatment, and this can lead to a situation where the contact situation is (often dramatically) changed. The mandible can even move bodily and laterally and suddenly slopes are used which could not be reached before. This should be reported by the patient immediately, and adustments will be done right away.

Most important is an early control of the occlusal and masticatory situation. We inform our patients to turn up for controls within max. three months after the end of the initial treatment.

And finally we would like to mention here that combined influence of the AFMP and the APPI can lead to unexpected deviations of the mandible and the reason must be sought. Keep in mind that also technical abutments are often the source of such interferences.

1.7.2. Case Study

(Published in: CMF Impl Dir, 2018, Vol 13, No. 1)

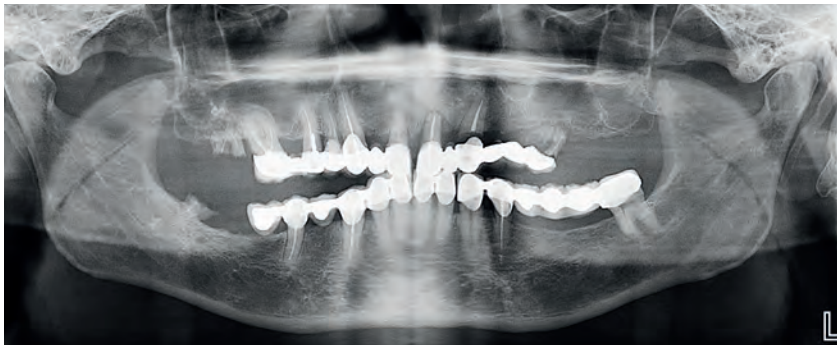

Fig. 1.14a *Pre-operative panoramic picture. The patient requested placement of implants and restoration only in the upper jaw. There is a severe APPI-discrepancy between the left and the right side in the lower jaw. Hence the lower jaw requires (massive) adjustments, mainly on the right side of the patient. Before treatment the patient is habitually using the lower jaw to the anterior and it seems that his skeletal class (acc. to Angle) is Type 1.*

Fig. 1.14b *The segment bridge in the right lower jaw is prepared for bonding a composite occlusal build up to it.*

Fig. 1.14c *The post-treatment picture shows the composite build up in situ, as well as the upper bridge (made from metal-acryl) in place. Now both APPI are identical.*

Fig. 1.14d *(615) MFC "overcrowns" on the left lateral segment. The lower front was reduced already, but it is still too high.*

Fig. 1.14e *(610) To avoid functional contacts between the upper and lower front the fronts have to be kept apart by a sagittal step (which is the biological result of the Angle Class 2 skeletal jaw relationship).*

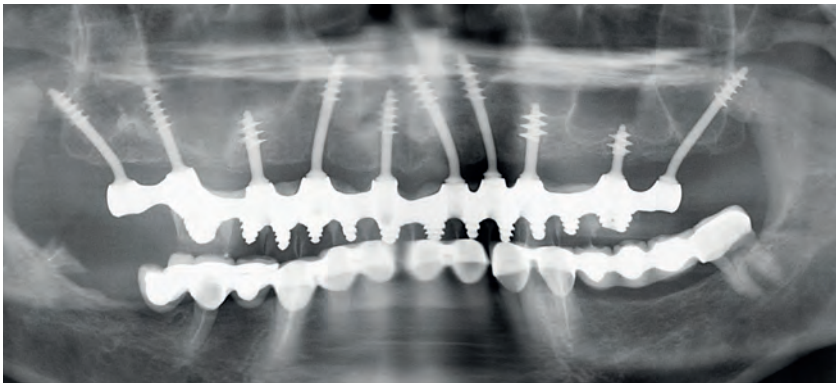

Fig. 1.14f *Panoramic overview picture after treatment. Since the patient insisted on keeping the (non-suitable) reconstruction on the lower jaw in, that construction had to be adjusted massively (and at extra costs). Without these adjustments in the lower jaw, the treatment of the patient in the upper jaw would not have been possible/advisable. Area 27 was produced without veneering; occlusal contact are available from 4-6 on both sides. APPI was corrected on the left side.*

1.7.3. Clinical implications

1. **APPI-concept** will determine if a single jaw implant treatment in an immediate loading protocol is possible without making (sometimes) significant changes in the non treated jaw. We can treat one jaw only, if the APPI is identical in the lateral segments of the non treated jaw.
2. Likewise the **APPI-concept** has to be obeyed when full mouth reconstructions are done. The advantage of treating both jaws at the same time with implants in immediate functional loading is that we (with the help of the dental technician) have automatically full control on all parameters and also on the APPI.
3. The **APPI-concept** is applicable and important for dentitions without contacts between the upper and the lower front teeth. Individuals with frontal contacts (i.e, with their own teeth) can masticate well even if the APPI on both sides is (very) non-identical.
4. If functional blockades are detectable it has to be determined if the problem has occurred due to an **unequal AFMP** or due to an **unequal APPI**, or both.
5. If the APPI is not identical it is impossible to determine the joint centric because the patients will not be able to reach posterior occlusal centric in a reproducible manner.
6. The APPI concept is concerned only about the inclination of plane antero-posteriorly and not the height of the plane. The heights of the planes in the individual patient can be different on both sides.

1.7.4. Number of Teeth per Jaw and Segment

During our work on teeth we have learned that all kinds of teeth are helpful to fix bridges, almost regardless of their position. Namely 3rd molars are assumed to be a last joker in the fight against mobile dentures, and for this reason these teeth are often kept throughout life and they are even used for (unilateral) bridge anchorage. As long as this is done symmetrically in one jaw, the damage is limited. As soon as constructions are non-symmetrical as shown in Fig. 1.15c, our work will help the patient to become functionally one-sided and hence potentially disabled. Note that unilateral use of the jaw-bone will result in an altered pattern of chewing and subsequently in an altered pattern of bone mineralization. Implants will become mobile under those conditions, because on the chewing side the bone will be overloaded, while the non-chewing side will become a tension zone and undergo changes known as disuse-atrophy (disuse osteoporosis).

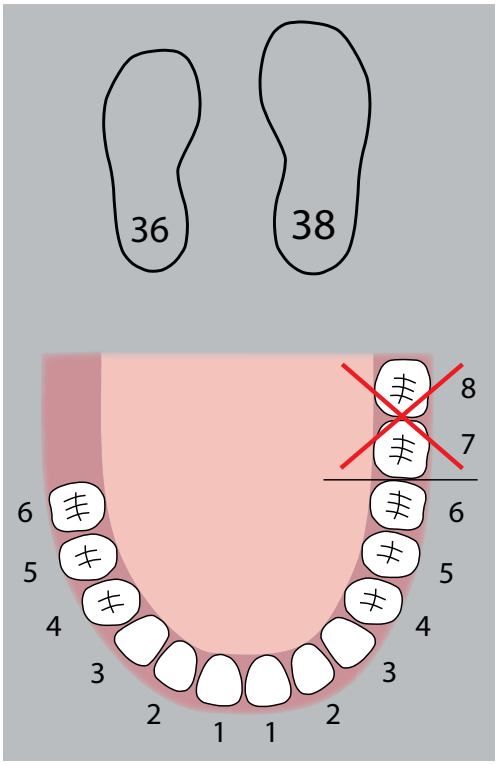

Fig. 1.15a *Just as a person could not walk symmetrically with shoes of different sizes, he/she will not eat symmetrically with an unequal number of teeth on both sides. Typically the side with more teeth is developed as the chewing side and contacts in the distal area of this side will occur first, and this is associated to overload-damage in immediate load implantology. On the non-chewing side damage caused by non-use will prevail. Note that the situation in both jaws will always have to be considered.*

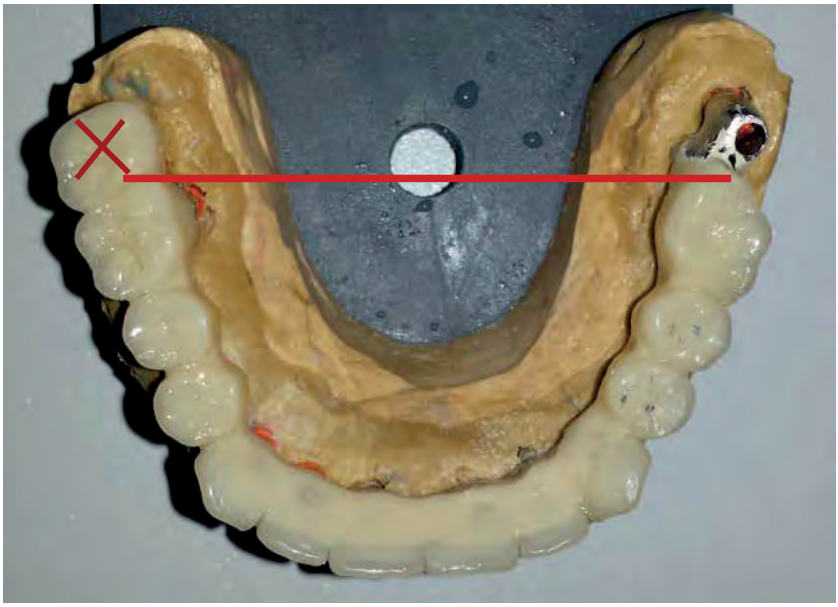

Fig. 1.15b *Clinical example of such an unsuitable bridge with unequal amounts of chewing surfaces on both sides. Tooth No. 27 must be removed from the bridge and an open technical abutment will be created, just as on the other side of the bridge. Note that contacts on polished technical abutments are not easily detectable. Therefore the treatment provider must explicitly search for and eliminate them.*

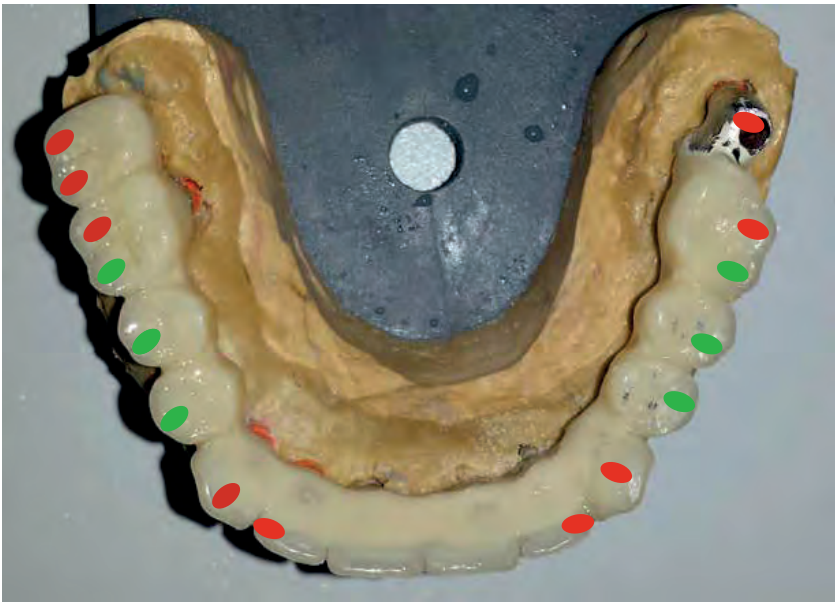

Fig. 1.15c *Even if the artificial tooth 27 is not removed, no occlusal nor masticatory contacts are allowed except on the premolars and the anterior half of the first molar. Green slopes: allowed slopes during mastication, Red slopes: Not-allowed slopes during mastication.*

1.8. "Balanced" Mastication[3] and the Supporting Polygon

When fabricating full bridges, one goal of the therapy is to avoid (unilateral) extrusive forces around the load transmission surface of the implants inside the bone. This way the bridge is pressed intrusively at all times and everywhere, all forces are intrusive. This is important for quality and quantity of bone retention.

However, there is not such a strong need for a balanced mastication anyway since we have osseo-fixated implants to keep the bridge in place. In order to prevent damage to the bone tissue we must avoid a.) mechanical overloading, and b.) regional, functional derived decrease of the mineralization. Both events may result in implant instability.

Note: Unilateral or anterior patterns of chewing must be strictly avoided!

3 The term "balanced occlusion" is used for full dentures and describes the (ideal) situation where both lateral segments are always in equal contact during lateral movements. This type of situation may help keeping lower dentures stable during mastication. For our work on Strategic Implants there is no need to create this situation, as long as the AFMP is identical and all other circumstances allow bilateral equal mastication. This will avoid the development of tension zones and make sure that enough intrusive forces are present on all implants.

One can imagine the mastication as a process taking place atop a polygon that is set up by the implants in the canine region and the most distal implants. All other implants increase cortical retention and stability while not expanding the polygon:

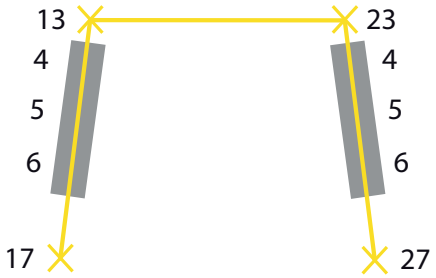

Fig. 1.16 *If occlusal contacts are only placed on the palatal cusps of two premolars and the first molar, they are inside the supporting polygon with certainty. This polygon is marked by implants in the area of the 2nd molar and the canines (yellow X, area 17, 13, 23, 27). Additional implants within the alveolar crest will not change the size of the polygon significantly. Note that the yellow crosses show the position of the abutments and not the position of the load transmitting surfaces of the implants*[4]*. The inclusion of zygoma implants does however increase the size of the supporting polygon and this increases stability against lateral forces. Note however that the concept of the supporting polygon works only if the frame of the bridge is rigid. We usually achieve this by metal frames (CoCrMo) with a dimension of no less than 3mm height and 2 mm width (depending on the distance between implant heads and the number of implants within the construction). Zirconium frames (or full zirconium bridges) also serve well. Bridges made only from acrylic must have a significant dimension to become stiff and this conflicts with the patient's demands for freedom of the tongue and good speech function.*

1.8.1 Avoiding Mechanical Overload through Bridge Design and Implant Positioning

Whenever possible, we will position occlusal contacts and slopes for mastication inside the supporting polygon. This will be easier in the lower jaw, where the resorption leads to a wider masticatory table in the distal mandible (centrifugal resorption). In the upper jaw we have to accept centripetal resorption and therefore a number of contacts will be outside the polygon. In cases of extremely small maxillae we should consider using BAC-Implants (Sub-Implants) and fix them on the bone crest towards the zygomatic bone, or we can use zygoma-screws right away. Both types of implants will widen the supporting polygon significantly.

4 See booklet 1, dealing with the treatment planning, for more information regarding the possibility of designing the supporting polygon.

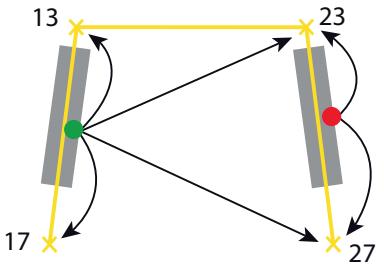

Fig. 1.17 *If occlusal contacts are located inside the polygon (green point, left side of picture), the forces are distributed through the rigid bridge to all implants (17, 13, 23, 27).*
But if occlusal contacts are outside the polygon (red point, right side of the picture), only the implants 23 and 27 are able to receive intrusive loading. Extrusion forces will prevail on the other side of the bridge (i.e. 13 and 17 are loaded on extrusion) and the implants 23 and 27 can act as a fulcrum. As long as masticatory function is bilateral, this disadvantageous situation may be acceptable and may not lead to overload-osteolysis. However, a unilateral pattern of chewing, e.g. on the left side of the patient (red point, between implants 23 and 27) will lead to an overload osteolysis.

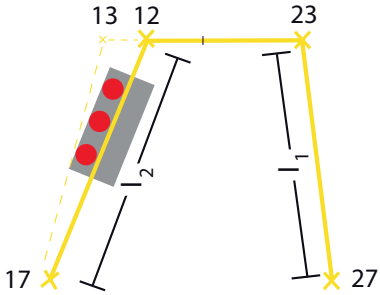

Fig. 1.18 *In this example one anterior corner of the polygon is moved to the medial (12 instead of 13). This change is connected to two major disadvantages:*
- *the length of the distance between the anterior and the posterior implants becomes too large (L2 vs. L1)*
- *all possible occlusal contacts in this side are outside the supporting polygon. A correct placement of implant 13 would ensure that all these contacts would be* ***inside*** *the supporting polygon.*

Even with the most rigid frame a situation as shown here will not lead to success: implant instability is likely to occur.
In a situation as shown here, at least one more implant in the position of the first premolar is mandatory.

1.8.2. Avoiding Mechanical Overload Through Design of the Masticatory Function

We have the possibility to determine how the masticatory function of our patients will look at the end of the treatment:

- By strictly avoiding anterior contacts in occlusion and function, we avoid an undesirable anterior pattern of chewing[5]
- By creating a bi-laterally equal AFMP we will avoid unilateral patterns of chewing
- By creating a chewing table (premolars and molars in occlusal and masticatory contact) of the same length and width, we will avoid again unilateral patterns of chewing

5 During growth all individuals will change the pattern of chewing several times in different phases of the formation of the dentition. Whenever better chewing options are given in the front (e.g. after eruption of the sets of frontal teeth), they will change to an anterior pattern of chewing. If later posterior teeth are available and erupt, the pattern of chewing will predominantly use these teeth and become a lateral one. In general: over-erupted front teeth prevent lateral patterns of chewing (typically found in Angle Class II/2 patients). The morphological changes are summarized in the "Kelly Syndrome", and untreated this state tends to aggravate.

If all this is done, the patient has no other choice but to use both sides equally and develop a lateral pattern of chewing. This is the safest solution for the survival of our immediately loaded implants.

1.9. Specifics of Tooth Morphology in the Lateral Lower Jaw

1.9.1. Lower 1st Molar

In German textbooks for prosthetic dentistry we find the term "Kronenflucht". This term describes a condition predominant in lower molars, in which the vestibular cusp is inclined lingually and situated in the centre of the tooth (Fig. 1.19 - 1). We have not seen the term "Kronenflucht" in any non-German textbook. However, this detail is important for uninhibited laterotrusion and especially for segments.

Dental technicians today usually do not know of this detail. Therefore we are confronted with crowns and bridges in the distal lower jaw where the vestibular cusps are situated far too much towards the vestibular (Fig. 1.19 - 2)

In such cases the upper vestibular cusps are blocked too much by the malpositioned lower vestibular cusps. Whenever we see this, we have to remove substance from the lower molars on the vestibular side (as shown in Fig. 1.19 - 2).

This must be done before we start the prosthetic part of the implant treatment, because such correction results in loss of vertical dimension. This loss will be corrected through longer (higher) teeth in the upper jaw. Only after a correction the BULL-Rule (grind: Bucal Upper cusps and Lingual Lower cusps) applies for future grinding.

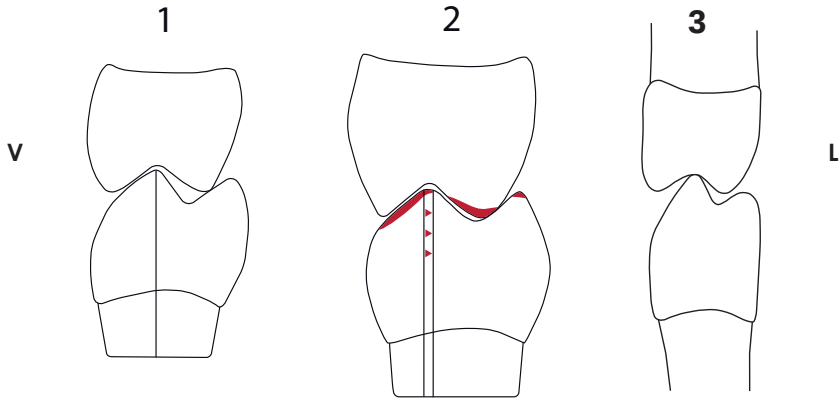

Fig. 1.19 *For good function the vestibular cusps of lower molars must be inclined lingually, in the centre of the roots*[6].

Fig. 1.20 *Contacts on the vestibular slope of lower first molars as shown on the distal aspect of the lower 1st molar, are always undesired and must be taken away. Such contacts will lead to an overly 1st-molar-driven laterotrusion. Patients do not notice this problem but as soon as we take these contacts away, they feel immediately relieved.*

6 Note that two solid bodies will have contacts only in 3 points at most. If a chair with 4 or 5 legs does not rock on the ground over an axis it must have been designed with a minimum of structural elasticity to allow deformation through its own weight. Creating more than 3 equally loaded contacts between the upper and the lower jaw works usually only thanks to the elasticity of the bone and the resilient suspension of the teeth.

1.9.2. Lower 1st Premolar

Especially in Class II-cases the inclination of the lower first premolar can be so unfavorable that contacts as shown in Fig. 1.19 - 3 cannot be created without designing an overly wide upper bridge.

Note that the chopping STOP-contacts of the 1st premolar are a very important factor for the function of the masticatory system. If these STOP-contacts are missing the masticatory system is disoriented and it is impossible to control the mastication. Therefore the system will always actively seek these contacts, even through an otherwise unnecessary forward displacement of the lower jaw. In the worst case the contacts are replaced by contacts between lower premolars and upper canines, while the jaw moves anteriorly.

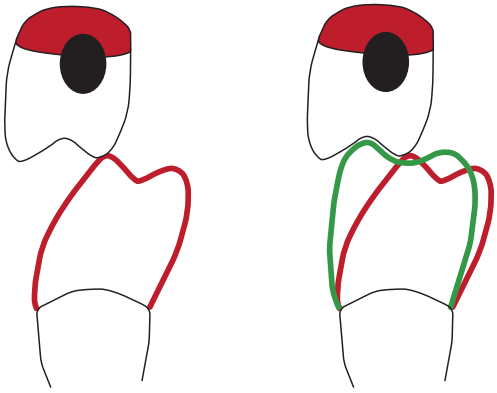

Fig. 1.21a *If the mandible relapses in skelettal class 2 cases, often the lower 1st premolar has to be crowned in order to provide the possibility of contact between upper and lower premolar. In addition the position of the frame of the upper bridge can be adjusted to the situation so that the upper 1st premolar comes into a more suitable position.*

Fig. 1.21b *The upper 1st premolar hardly touches the vestibular cusp of the lower 1st premolar. In order to reach a normal intercuspidation the lower 1st premolar must be crowned.*

Chapter 2

Treatment in an Ever changing Environment

2.1 Introduction

When opening the mouth the mandible position is determined by the joint surfaces and the muscles. During occlusion and mastication the position is determined by occlusal contacts and by masticatory slopes.

At the onset of every treatment the bite (occlusal position of the mandible) of almost all adult dentulous or partly dentulous patients should be assumed to be "wrong", i.e. in this position the teeth may be in technically correct contact, but the condyles are not simultaneously in the centre of the fossae, and the muscles are not equally relaxed on both sides. Most of our patients have no problem achieving the wrong bite from this starting point, and using teeth and muscles to return to this position.

Wrong means:

- The centric occlusion is not reached with both condyles in the centric position
- Should the patient relax his masticatory muscles completely and close his/her mouth, this would not result in maximum intercuspidation
- In patients with front teeth: if these teeth are in contact, they automatically deviate the condyles (typically: push them backwards), even if the deviation leads to a "correct" or "full" intercuspidation

The masticatory muscles on both sides are innervated from one single nucleus in the brain. This means: the muscles on both sides of the mandible are forced to work in friendly mutual co-ordination. It is obvious but it must be mentioned here: it is not possible to close the mouth with one masseter muscle and to open it at the same time with the contra-lateral masseter muscle. If either occlusion or mastication prevents a smooth, co-ordinated function, problems arise. This explains the significance of the prosthetic work.

2.2. Why Is the Bite Almost Always Incorrect?

The elements included in the chewing process (teeth, bone, joint surfaces, muscles including their neuronal steering joints) have certain abilities to compensate changes of the other participants.

Even on integrated Implants (whether anchored in the first or second cortical) the position of the tooth arches in relation to each other will change over time due to changes of the morphology of the bone. This will have effects on the occlusal situation and on the functional possibilities of the masticatory system.

Astonishingly patients maintain a more or less effective chewing function despite the run down dentition and only a few teeth meeting in a small number of points. Our brains are trained to optimize the process of chewing by utilizing the best available chewing surfaces. This works even if there are a lot of possibilities to make different tooth surfaces meet and work together to create "masticatory function". The brain will always choose the contact that is easiest and most successful with the least amount of effort.

In fact the "well reconstructed" (crowns, bridges, dentures) but not functionally maintained (no adaptational grinding, missing bite lifting, etc.) dentitions are usually the ones to reach a status of functional disorder.

The brain optimizes effort for result, consequently our patients prefer to:

- Utilize the most distal functioning chewing surface
- Utilize the side where a longer plane of chewing is available (e.g. left side of patient in Fig. 1.15b)
- Utilize the side with wider chewing surfaces

On the other hand patients will preferably utilize the frontal group for chewing, if:

- No other teeth are available
- The frontal group blocks utilization of the premolars and molars (e.g. in Angle Class II/2 this can be observed)

This is the aim of our treatment: to create a functional situation, in which teeth are not blocking the lateral movements and where slopes of the cusps guide the mandible in harmony with the functional possibilities of the muscles and the possibilities of the joints.

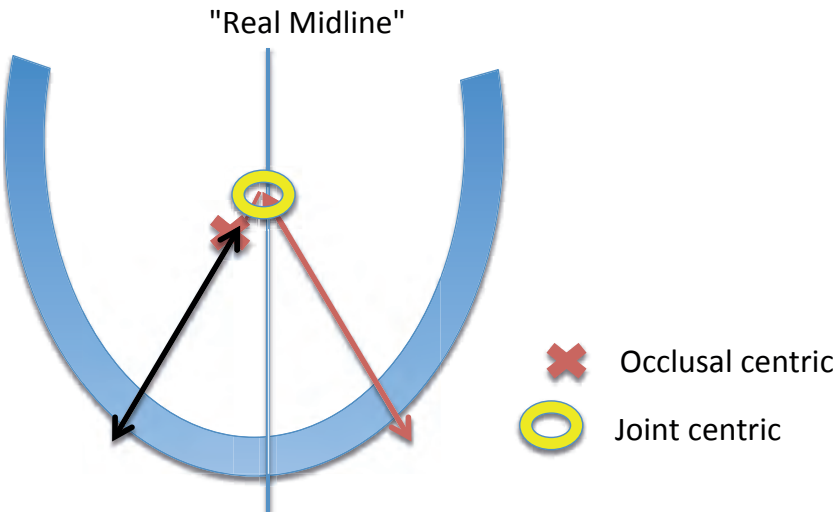

Fig. 2.1 *In this example, the occlusion centre (point **X**) is not identical to the joint centre (point **O**). As a result, the patient will move the lower jaw to the right side "as normal". When moving to the left side, however, the joint centric must first be reached before the actual laterotrusion is possible. This movement pattern is clearly recognizable and it shows that the occlusion centric does not match the joint centric. In such an anatomical-muscular starting position, the patient must first lead the lower jaw to the centre of the joint through muscle-guided movement before he can make lateral movements to the left. In the case shown here, the two lateral lines of the AFMP can lead to **one end point** as shown in Fig. 1.9d-f, or to **two end points** as shown in Fig. 1.11a. Such a deviation of the occlusal centric can be the result, for example, of massively uneven abrasion, whereby the vertical dimension is reduced on one side. Since the muscles of the lower jaw always try to create a situation in which both sides of the lower jaw are supported, such lateral displacements of the lower jaw in occlusion can occur.*

2.3. How to Recognize the Incorrect Bite

There are a number of indicators for this.

- If the midlines of the centrals are not in alignment, we should think about a faulty positioning of at least one of the tooth arches, or about functionally derived discrepancies in the size of the arches
- Exceptions to this rule are unilateral extraction cases and other unilateral tooth loss in early age
- Deviations during the opening of the mouth are an indication of a wrong rest position of the mandibular joints
- The morphology of the mandibular joints is unequal, or the morphology has changed significantly from standard joint morphology
- When asking the patient to move to the left and the right, the mandible will initially move a bit centrally and backwards on one side, before moving freely to the requested side. This indicates that the mandible did not start the lateral movement from the rest position of the joints (i.e. not from "joint centric")

2.4 How do the Components of the Masticatory Apparatus Alter the Position of the Masticatory Surfaces?

2.4.1. The (Jaw) Bone

Wolff's Law (1892) described the fact that bone optimizes its weight and morphology with respect to mechanical demand. This law is true for all bones and also for all life. Hormones have a strong influence on the amount of bone created or reabsorbed, i.e. on the baseline remodelling rate (i.e. remodelling without any surgery or fracture or overload on bone)[1]. In the dental field the growing dentition creates bone which is required only while and where the teeth are present and sufficiently in function. After tooth loss the amount of bone is reduced through the process of "atrophy". The term "atrophy" describes missing nourishment for parts of the bone after teeth are extracted. Another possible reason for bone loss is reduced muscle function and the fact alone that the bone optimizes its morphology constantly while it is remodelling. Note that atrophy may occur from inside or outside the bone, i.e. either on inner or on outer surfaces (or on both surfaces) bone may get reabsorbed. Resorption from inside will be invisible from the outside and even go unnoticed on x-rays.

1

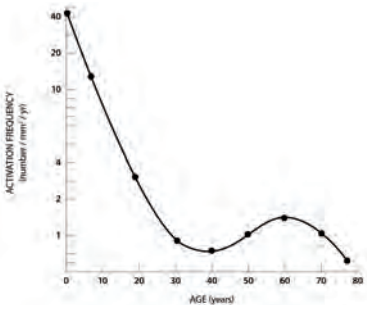

Fig. E2 During growth of an individual we observe a very high remodelling rate of bone (measured as number of new osteons/mm2/year). From: Martin RB, Burr DB (1989): The structure, function, and adaptation of compact bone. Raven Press, New York.

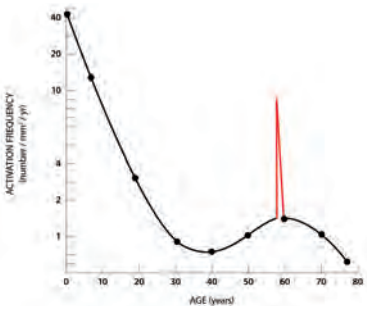

Fig. E3 If fractures, surgery, or even just damages to the periosteum occur, a local increase of the osteonal remodelling is found for a short time. As long as the overall musculo-skeletal function is not altered, all other bones of the affected individual keep their age-related osteonal activity.

The temporo-mandibular joints (TMJ) are part of the masticatory system. The joint's morphology may change throughout life. The TMJ is equipped with fibrous cartilage and this type of tissue may (other than hyaline cartilage) undergo quick and dramatic morphological changes. We can even follow the change of morphology on panoramic pictures. Luckily most implant patients appear in our offices at an age when their overall bone remodelling rate is low.

To summarize: the morphology of (jaw) bone changes constantly. If we assume that teeth are in a fixed position relative to the crest of the bone, the position of teeth will therefore also change. There is a difference between traditional crestal implants and basal implants:

- crestal implants are predominantly integrated in the first cortical and follow the morphological changes of this cortical (or they become prey to peri-implantitis).
- basal implants are fixated in the 2nd cortical and passively allow morphological changes of this cortical (if there are such changes). This is a dramatic difference when it comes to predicting the changes in the occlusal situation, the relative vertical position of the teeth, and the effect on the patient's mastication.

2.4.2. Changing Tooth Positions

Stable teeth give the impression of being embedded in concrete. Nevertheless teeth have a slow tendency to change their position and spatial relationship. The most important tendencies are summarized here:

Tilting Teeth tend to keep the level of the bone parallel to the line between enamel and root-cement.

Elongation Teeth in mechanically activated segments tend to move towards the plane of bite unless intrusive forces stop them. Thus elongation can take place with and without the bone.

Active Intrusion Teeth may also be intruded through high masticatory forces. If such intrusion happens to upper front teeth, gaps develop and the teeth wander laterally. In unilateral patterns of chewing we find a combination of elongation (on the non-chewing side) and intrusion (on the chewing side). This results in a change of the plane of bite. It is unclear if this development takes place both in the upper and the lower jaw, or if plastic deformations of the jaws are the underlying reason in at least one jaw.

Loss of Vertical (passive intrusion)	Teeth in non-activated bone segments following the changing vertical position of the bones crest like a ship in waves. For this reason especially upper 2nd molars lose contact to the lower dentition after extraction of the 1st molars and premolars. They passively follow the contracting bone level, resembling an intrusion. The bone in the maxilla contracts (upwards) towards the base of the skull, while the bone in the mandible contracts (downwards) towards the lower rim of the mandible.
Migration	Teeth also tend to show a movement along the arch. Depending on the form of the root, teeth usually migrate towards the midline. Lower premolars move distally in most cases.

2.4.3. Muscle Activity

Fine steering of very strong muscles allows for directing forces to specific chewing surfaces. The brain seems to optimize the necessary forces by using predominantly posterior teeth for hard chewing work. If teeth are lost in one segment, muscular activity will be reduced (even to 0), probably because vertical forces would cause damage and subsequent pain in the TMJ. Posterior teeth protect the TMJ from such damaging forces.

2.4.4. Changes in the TMJ's Morphology

In an ideally functional environment the joints have no reason to change their morphology. An ideally functional environment is given in most Angle Class 3 cases, for example. These patients show a symmetrical hinge movement of the TMJ and no anterior movements. Their joint position is stable. Anterior movement of the jaw makes no sense for them because the lower jaw is advanced anyway.

Angle Class 2 patients usually show a bilateral anterior flat surface of the joints. The patients move their jaws anteriorly in order to chew.

Patients with long-term edentulous segments show these flat anterior surfaces of one joint on the non-chewing-side. As soon as they switch sides for chewing, the other joint becomes anteriorly flat over time.

Angle Class II/2 patients show bilateral anterior flat surfaces on the TMJ. Patients with long-term unilateral function show enlarged and round(ed) joints on the chewing side, and flat anterior joint surfaces on the non-chewing side.

Considering the mentioned changes in position and morphology, we can only wonder how it is possible that throughout childhood, growth and a long adult life our teeth usually manage to touch each other and give us the possibility to chew.

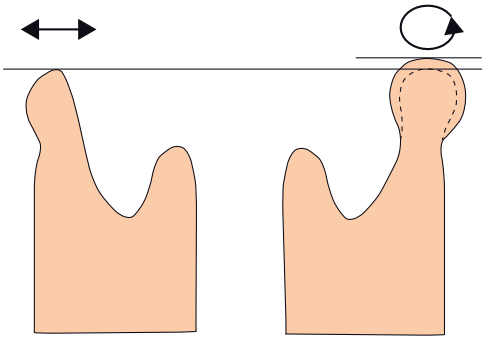

Fig. 2.1a *If patients live with a unilateral pattern of chewing for some time, the joint on the chewing side (here left joint of the patient) increases in size and stays round, while the joint of the non-chewing side becomes anteriorly flat. This probably includes an increase in the vertical height of the condyle. This is compensated for by other changes in the bone morphology and by elongations.*

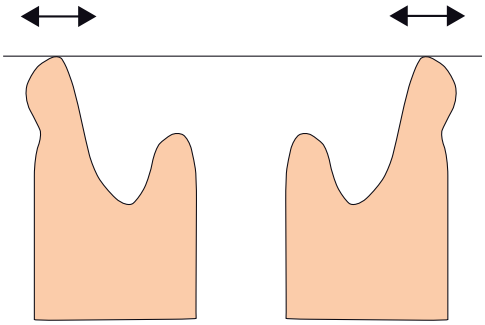

Fig. 2.1b *If a patient as shown in Fig. 2.1a loses the chewing ability on the working side, he/she might switch function to the non-working side at a later stage of life. This results in bi-laterally flat anterior TMJ surfaces and in an unstable sagittal position of the mandible. The same type of joint morphology is also seen in all Angle Class II/2 patients. Such joints do not have a reproducible centric position in the fossa, and bite-taking is difficult and non-reproducible (unless a backward angle index is used). Muscular strength and occlusal orientation determines "the bite" more than the joint's morphology*[2].

2 In dental literature and teaching the idea is expressed that the masticatory and mimic muscles should be "passive" (relaxed) and then the TMJ centres according to the joint's morphology. TENS therapy is based on this idea. We believe that a fully passive joint position can only be reached if all muscles are dissected off the mandible.

We know from our experience with botox therapy to the masseter muscles that deactivating this muscle on both sides results in an anterior positioning of the mandible with only contacts on the front group remaining. We must assume that all masticatory and mimic muscles participate with multiple force vectors and influence the joint position. Changes in the strength of single muscles influence the joint position instantly, while the intercuspidation tries hard to keep the position of the mandible stable. The TMJ, being a fibrous joint, will even react with morphological changes to a new force environment in the long run. Note that all other joints in our body (i.e. hyaline joints) do not have this possibility of undergoing healthy changes to the joint surface morphology.

Fig. 2.1c *Post-traumatic stop of growth on the right side of the maxilla prevented any masticatory function on this side. Consequently the left condyle is round and well mineralized while the condyle on the right side is deformed, lengthy, and shows a reduced size.*

Chapter 3

Diagnosing the Masticatory System

3.1. Ineffective Diagnostic Procedures

Some practitioners and teachers still believe that the habits of "gnathology" lead to good and stable prosthetic results. Measuring of Bennett-angles, using the functionally generated path (FGP)-technique, and other procedures have been advocated, but the results are doubtful or even potentially dangerous. Typically these procedures will help transfer the former pathological situation into the new prosthetic construction working under the same pathological pattern of function, rather than allowing the masticatory system to find a new balance and function, and creating real oro-functional health.

Other than, for example, when it comes to fight bacterial infections with specific antibiotics, we do not need extensive diagnostics on the TMJ to create a functioning mastication.

We know how the healthy status looks and how the joints work and the mandible moves. Hence we should always work directly towards this healthy status, regardless of the pre-treatment situation. Often remaining teeth prevent the desired result. As described in booklet No. 1 there are a large number of good reasons for the elimination of such teeth.

3.2. Effective Diagnostic Procedures

Before treatment onset we have to note if the patient is able to deviate the mandible to both sides while under contact. Patients with long-term unilateral chewing are more difficult to treat because their system is not able to utilize both sides at the beginning of the treatment, since it is not used to doing so.

The presence alone of well-designed new chewing surfaces on both sides will not make the patient use those surfaces equally. If the possibility of movement is limited to one side by muscular inability to move the joint (resections of bone-parts creating an interruption, e.g. of the mandible or resection of muscles, paralyzed patients), setting up of a bilateral equal mastication is impossible. Such patients are better off not receiving treatment in immediate load protocols, or the amount of cortical anchorage must be severely increased. In such cases combining compression screws with basal screw implants is recommended.

If only functional blockages are present, they can be overcome. But it takes time and patients must be motivated to practise using both sides. In other words: even if we have installed acceptable functional paths for mandibular movements (masticatory surfaces), some patients may remain blocked in their movement and will not use them. This situation must be diagnosed and we must find a way to overcome this obstacle. The next most important diagnostic step is to determine (by clinical means) the correct sagittal position of the mandible in the correct vertical dimension. This may cause difficulties in the beginning because the patient often refuses to bring the mandible to the most dorsal position named "joint centric". Especially in functionally run down stomatognath systems, this centric, which is determined solely by the morphology of the joints which are preferably under no muscular influence, may be avoided by the patient. Instead the patient moves into a habitual mandibular position. This is often seen in patients who used an anterior pattern of chewing and whose upper anterior teeth have moved outwards with the mandible following them functionally.

Often patients with a skeletal Angle Class 2 refuse to move their mandible into the most dorsal, joint centric position. We can support them by letting them bite on an anterior jig or by applying a support-pin procedure (Stützstiftregistrierung) just as when registration for full dentures are done. Once we manage to direct the mandible into the dorsal centric and keep it there, the functional pattern can be the same as in Angle Class 1 patients.

In **complex cases** it may be helpful to fabricate individual impression trays with mounted wax blocks (sufficiently warm wax). This way parallelism of the plane of bite to the plane of Kamper can be controlled and the vertical dimension can be registered simultaneously when taking the impression. The procedure is the same as in full dentures, except that the individual impression trays are now mounted on the implants (to avoid the errors created by the resilience of the mucosa).

Facebows (which allow us to create tooth arches that fit to the nose and the ears!) are useful in obtaining a good approximate positioning of the upper jaw model in the articulator, but the results of the facebow application must be controlled. Facebows are not applicable if the maxilla-facial complex shows severe asymmetries.

The best orientation of the upper jaw model in the articulator is reached by a HIP-mount and Head-lines devices (http://mediplus-shop.de/Physio-Logic--Articulation/HIP-Mount-Serie-8.html).

3.3. Preparing Existing Occlusion and Mastication

If unilateral segments are replaced, the patient will keep part of his own dentition and it is our first job to adjust the occlusion and the mastication in this part of the jaw, that is on the patient's remaining teeth or crowns/bridges. This should be done at the latest before the final impression is taken. Incompatible contacts and slopes must be eliminated to allow a free gliding of the mandible to the working side. As this affects the AFMP angle, we must do this step now. Failing this, dental technicians cannot take into account the functional effects of the occlusal adjustments in their work, and in many cases the patient will continue to exhibit an unilateral chewing function. In addition, double bites may occur (i.e. two different subsets of what would constitute maximum intercuspidations on the left and right sides, while maximum intercuspidations on both sides cannot be attained simultaneously).

If only isolated segments are restored on implants, the resulting intercuspidation must be carefully analysed – and usually adjusted – in this segment. A failure of an implant-supported segment after immediate loading is often caused by pre-existing bite problems; the dentist may have believed that the existing bite was correct, or the adjustments did not completely reposition the joint in centric. The basic problem is that on the non-implanted side, the occlusion will determine the position of the mandible, while on the implanted side, the temporomandibular joint will determine it.

Due to their positions in the jaw, third (or in some cases even second) molars will (continuously) elevate the bite in the distal region, resulting in premature molar contacts. Subsequently the frontal group and premolars elongate (with or without bone). If pockets appear in cases with elongations, periodontal infection develops and the case is wrongly classified as a case of "periodontitis". We should actually classify this as a case of "chronic and superinfected elongitis", for which the only treatment that truly addresses the underlying condition is orthodontic treatment. To avoid further elongation 3rd molars must be always removed as part of the initial treatment. Third molars are exempt in some cases when they are fully cortically (mostly horizontally) impacted. If existing crowns and bridges require extensive changes that cannot be carried out right away, we have to renew them or prepare them without taking the metal frame off. Then the occlusal surfaces are replaced with (lab-fabricated) temporaries from composite or acrylate. This allows creating an adequate opposing dentition and at the same time the temporaries can be adjusted easily. Transferring a proven temporary situation into new definitive restorations is then a rather easy task.

Chapter 4

Bite Registration on Implants and Bridge Frames

If the patient's masticatory system has lost all orientation and when it functioned under wrong bite situation, the patient has almost no chance to assist the treatment provider when it comes to take the bite. In these cases the dentist must closely observe all movements of the jaws and control the result of the bite registration. We usually prefer fast setting silicone for this procedure, because we can apply the material very slowly. As it sets in some areas, it is possible to add material in others. After everything is set, the bite is taken out and undercuts are removed. The mandible needs adequate freedom of movement to attain joint centric – and the patient will often need a certain amount of time and practice to move the mandible to that position. Then we add more material to register this position. The result is probably usable if the patient finds the same position immediately.

Fig. 4.1a *The bite on implants is registered here against a lower dentition with warm, pink wax.*

Fig. 4.1b *Immediately after the bite is taken, the wax is cooled under running water and the same piece of wax is reinserted to control the result of the bite registration. In the case shown here the initial registration of the bite was not done in joint centric, i.e. the bite was falsely registered anteriorly. This result is often found in Angle Class II-patients and in patients with an anterior pattern of chewing*

If the patient doesn't find the same bite right away during the control, we apply an anterior jig (e.g. made from light cure composite) which is fixed to the upper or lower front teeth, or one or several frontal implants. This jig also enables the reliable determination of the vertical dimension, i.e. the bite will then be registered in the correct vertical dimension and the jig becomes part of the bite. This jig may also be used as a slip-slide for the mandible to find a more dorsal position. In any case the opposing jaw will touch the jig only in one point, Fig. 4.2.

If we are unable to register the bite correctly, for instance if we constantly get different results, the approach must be changed. There are a number of possibilities:

1. "Anterior deprogramming" is performed by having the patient bite on a jig (ramp) for some time. This ramp can be mounted in either jaw, and it will have contact to the other only in one point. For example we can use one of our dental instruments as such a ramp, or we fabricate it with methacrylate or composite in the mouth. It is important to register the bite in the correct vertical dimension or in a minimally higher position. If the bite varies in anterior-distal direction, the jig must have an oblong shape to allow the lower jaw to move freely in order to allow deprogramming.

Note that avoiding the placement of temporaries between surgery and bridge placement (or at least until the frames are tried in) allows further deprogramming of the muscles before the 2nd bite is taken on the frames.

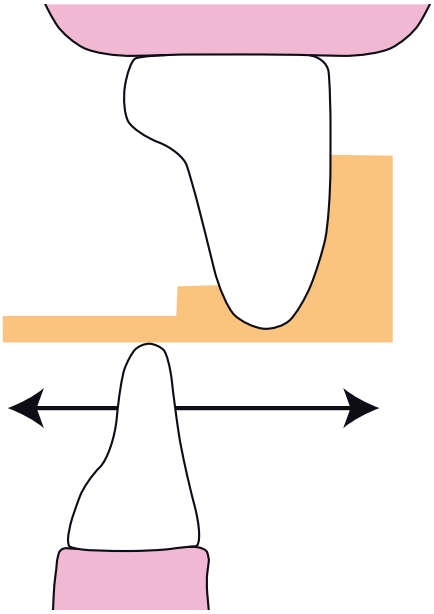

Fig. 4.2 *The anterior jig (ramp) is fixed to the upper jaw dentition and allows the mandible to move on a plane to anterior and dorsal. The bite is only slightly lifted. As soon as the dorsal position is determined, fast setting silicone for registration is added left and right to the jig, and later the jig becomes part of the bite.*

Fig. 4.2 a, b *The mandible can also slide anteriorly (right) and posteriorly (left) on a wide cement spatula. The vertical dimension can be adjusted by the angle under which the spatula is held inside the mouth. The spatula remains in the correct position while the bite is taken with fast setting silicone.*

2. Another option, especially if both jaws are restored simultaneously, is to perform a registration with the help of a single central pin on a plate just as in full dentures (Pfeilwinkelregistrat, gothic arch). For this procedure we need an individual transfer plate, which is connected to the heads of the implants.

3. If we become aware of the situation at a stage when the prosthetic workpiece is ready, we can use the concept of "Hanau's Schaukel Okklusion" (swing occlusion): contacts, for instance in composite, are created on the first lower premolar premature. Then the patient is sent home to his normal life. After a few hours – at most one or two days – the temporomandibular joint will relax and reposition, so that a slow and gradual reduction of the temporary contact makes it possible to detect the correct bite plane. The bite can subsequently be lowered again, or it can be built up on the other premolars and in the region of the first molar.

Chapter 5

Adjustment and Build-up of Occlusal and Mastication Surfaces

5.1. Introduction

The adjustment of the functional surfaces of full-arch and segmented bridges (as well as any necessary adjustment of the existing natural dentition and restorations) is carried out according to the following procedure, which is invariable. Adjustments are made in the following order:

1. Occlusion
2. Mastication
3. Protrusion

Steps 2 and 3 are accompanied by constant checking whether any changes in the occlusion have resulted, any unwanted anterior or posterior displacements of the mandible (in occlusion) have occurred or an anterior chewing pattern has developed (which can happen at any time due to the lowering of the vertical relation associated with adjusting the masticatory function).

The above sequence must be strictly observed: as long as the occlusion is not stable and identical on both sides, the masticatory function (laterotrusion) cannot be adjusted, and as long as the masticatory function is not identical on both sides, no adjustments should be made to the protrusion.

As a result, we must constantly and accurately monitor what patients are really doing when we ask them to close. This observation is just as important as identifying occlusal contacts and tracing movements.

Expert opinions on prosthetic restorations often state that "the dentist took the bite incorrectly", but while this could indeed have been the case, it is not so easy to prove after many weeks or even months. Bite registration is a process with a limited number of rules and a great number of uncontrollable variables. But even if bite registration was performed properly, possible changes in function (which are to be expected in each and every individual case) result in changes to the bite situation, which may well render the result of the underlying treatment useless. However, an "incorrectly taken bite" cannot be verified based on the basis of the occlusal situation as it stands at the time.

Admittedly, this is unfortunate for the patients, who tend to expect not only "good work for good money", but also "correct" and "lasting" results. Two important points deserve mention here:

- If we treat a functionally desolate dentition, there will be re-co-ordination of the masticatory muscles, with stronger and symmetrical masticatory muscles forming. This will typically lead to modifications of the positions of the temporomandibular joints (TMJs). This alone requires regular readjustment of the occlusal surfaces.
- Because the morphology of the bones (and not only of the TMJs) continuously adapts to changing needs in function, it is completely impossible to provide prosthetic restorations that are stable and continue to be correct over the long term. This is another reason why lifelong control of the occlusal and mastication surfaces is necessary. Our implants, regardless of whether they are osseo-fixed or osseo-integrated, are firmly attached to the bone and follow all the bone's changes. The occlusion and mastication surfaces must therefore also follow these changes, i.e. even perfectly matched surfaces will stop matching after a certain amount of time.

We believe it makes eminent sense to analyze and classify the functional status of a given dentition for setting up to perform a treatment:

A Perfect, well-co-ordinated function of the mandible, including an even bilateral masticatory pattern; stable occlusion.
B Unilateral mastication function, uneven timing of the main masticatory muscles at jaw closure; unequal palpated size of the main masticatory muscles; deviations at mouth opening with/without TMJ clicking
C Severely impaired co-ordination of the masticatory system, unilateral and completely obstructed laterotrusion, involuntary protrusion movements, sometimes even producing anterior crossbites in occlusion
D Complete lack of co-ordination of mandibular function and mandibular position.

Based on this assessment, the progress achieved in co-ordinating the masticatory function can be assessed, over the course of treatment. Patients cannot usually perform this assessment of their masticatory function themselves. Experience has shown that most patients can come to terms with even the most chaotic functional situations and regard them as "normal".

A patient who was functionally assessed as a class **C** or even class **D** case at the start of therapy can still receive fixed restorations on Strategic Implant® within 72 hours (3 days). However, this does not mean

that we can functionally bring this patient to a class **A** within the same amount of time.

Patients who present after years of unilateral chewing patterns are assigned to class **D**; they require regular check-ups. It can be helpful to allow patients to follow their own movements in a hand mirror during the try-in of fixed restorations. The mirror provides feedback, and patients learn more quickly not to assume involuntary protrusion positions.

A correct occlusal adjustment and the maintenance of a bilateral and uniform masticatory function are necessary for this reason alone, to ensure that stable and symmetrical conditions exist in the bone.

- Unilateral chewing patterns change the distribution of tension and compression in the bone (both in the maxilla and in the mandible). This results in overloading of the peri-implant bone on the masticatory (working) side, and osteoporotic bone develops on the non-masticatory (non-working or balancing) side, where tensile forces predominate. Both factors result in an instability of basal implants and blackening of the force-transmitting threads.
- Under the same conditions, the bone around crestal implants will produce areas of crater-shaped bone collapse on the balancing side, which will then be diagnosed as inflammatory "peri-implantitis" (according to traditional thinking on the part of crestal implantologists). However, the term "peri-implantitis" is misleading in these cases because the bone loss is functional in nature and infection only occurs due to the roughness of the implant surfaces.

5.2. Patient compliance and the reliability of patient proprioception

As we work on the functional details of occlusal and mastication surfaces, we will have to ask patients, again and again, where they believe they notice the first occlusal contacts on closure – on the left or right side. It is recommended to do this right at the beginning of the treatment session, while only a unilateral occlusion is present (something that only we know at the time). In this way we can test whether the patients' proprioceptive statements are correct and whether they are able to since and correctly report their perceived situation in the first place. Many patients actually cannot do that.

If we see that the patient makes incorrect statements and – for example – keeps confusing right and left, then we know that we cannot rely on patient feedback during any part of the process. Sometimes we can observe that patients increasingly learn what we mean by our questioning (and what response we are trying to elicit) and after a

while begin to grasp the situation and start answering our questions correctly.

We also have to take into account that not a few patients "force" their bite during the treatment session, doing what they think the dentist expects them to do. This, however, serves to conceal their true occlusal status, making occlusal adjustments impossible or at least very difficult (see section 5.16).

5.3. Articulation paper and other diagnostic tools

We only use thick occlusion paper for occlusal adjustment which leave well discernible traces.

Fig. 5.1 *Articulation paper with a thickness of 200 µm not only clearly shows the contacts and grinding marks, it also gives the dentist an idea of which of the contacts are strongest.*

We recommend working exclusively with a single type of articulation paper in order to obtain adequate and continuous practice in interpreting the visual result on the teeth.

The articulation paper shown here is also able to reveal situations in which it is not the vestibular cusp of the maxillary molars and premolars that provides guidance but rather the steeper palatal cusp. This is shown by pronounced, "multilayer" markings on the internal side of occlusal contacts. If these cusp slopes are flattened (which reduces the size of the "contact point"), the strong abrasion of the articulation paper disappears, with patients reporting easier lateral glides.

5.4. Objective of occlusal adjustments

The elimination of unilateral or unilaterally stronger occlusion contacts when the both TMJs are in centric position is the first goal when adjusting the occlusion. The position of the teeth and the occlusal contacts will depend primarily on the relative position of the jaws, i.e. on their Angle class (see Chapter 1 of this book).

It should be borne in mind that when adjusting the occlusion and mastication, the muscles, especially the pterygoid muscles, may react at any time – and this will have immediate dramatic consequences for the position and movements of the temporomandibular joint. Almost every patient – except patients with a true Angle class 3 relation, can at any time and abruptly assume a more retral centric joint position. This means that the occlusion will then have to be readjusted from the start in this new (presumably more correct) centric position. Such changes can occur even – or especially – during the first few days or within weeks or months. This was described as early as 1970 by A. Gerber in his article entitled "Occlusion theory, occlusion diagnostics and occlusion treatment in the change of our aspects" (Schweiz Monatsschr Zahnmed/ RMSO, 80:447–470). Gerber described the conditions governing the chewing and holding muscles, the temporomandibular joint and the teeth in great detail. At that time, he could not yet know about the enormous influence of osteonic remodelling, which was only discovered and described in 1968 by Frost in the USA. In 1970, nobody in Europe could have learned about these findings, and Dr Gerber could not relate his findings to immediate loading in oral implantology, simply because that discipline of dentistry did not yet exist. The basic relationships between functionally determined bone biology and the rules of immediate loading were comprehensively explained for the first time in the textbook Principles of BOI.

In this chapter, we often think and speak about occlusal adjustment as being performed subjectively by grinding, because occlusal and masticatory function are usually adjusted in this way. This means that, once the restoration has been delivered, the vertical dimension will usually be a little too high so that subtractive measures can be taken in order to adjust function without producing contacts on the front teeth, which should not occur either in occlusion or during mastication. The protrusion function is then also carefully adjusted, because the patient must be able to bite off an apple or bread without any problems or risk (and successfully of course).

If the vertical dimension cannot or should not be reduced any further, the goal can be achieved additively by "building up" additional substance. Composite-resin teeth are particularly suitable for this

purpose. Composites can be added to and built up with the standard tools available in any dental practice, which is why we now prefer this material to ceramics.

If only one jaw has been restoratively treated, the question often arises whether it is “better” to perform adjustments to the restoration on the treated side or to the natural dentition. As will be shown later, the correct place to perform adjustments will always present itself logically and clearly; it does not make sense to “conserve natural tooth substance” if it is in the wrong vertical position (i.e. if it is elongated or below the plane), shows unsuitable traces of erasure, presents with the wrong cusp inclination or has been tilted or rotated.

As things stand today, we consider the concept of lingualized occlusion to be the safest way to eliminate lateral interferences. It is primarily lateral forces that destabilize immediately loaded implants (in full-arch bridges and segmented bridges) – excessive chewing forces (alone) are rarely to blame.

A kind of lingualized occlusion occurs almost automatically when the mandibular premolars and molars show “crown alignment” and when the maxillary vestibular cusps are shortened.

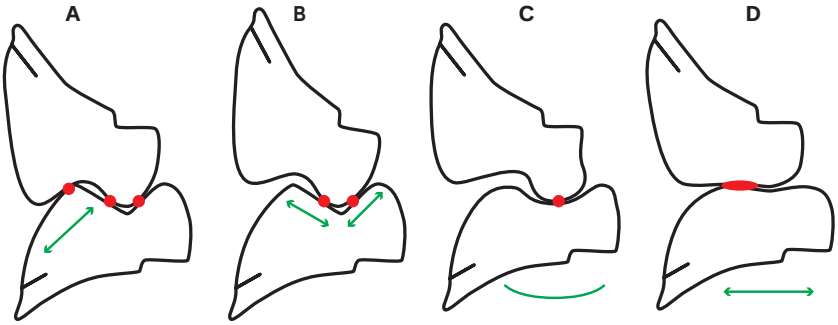

Fig. 5.2 a-d *This drawing shows three principal variants of teeth and indicates their interaction:*
A *Traditional tooth shape with "intercuspidation" with three or more contacts between antagonists. Often tripodistion is reached with these tooth shapes. Such teeth are not suitable for use in immediate loading protocols. The AFMP angle is determined usualy by the steepnes of the upper vestibular cusps. (Example: Phonares Typ II, Candulor).* ***B*** *The palatal cusp of the upper 1st molar is formed very prominently and shifts during mastication along the inner cusps of the molar. The AFMP is determined by these cusps. This anatomical variant of teeth leads to lingualized occlusion, but also to a forced bite position (Example: Phonares II Lingual).* **C** *The palatal cusp of the upper 1st molar is formed like a ball and it contacts to the groove in the lower molars in one point only. Lingialized/palatalized occlusion is guaranteed by these teeth. During mastication the upper vestibular cusps will never be in contact with the lower vestibular cusps (Gerber/Palla). We consider this type of tooth to be the most suitable shape for creating an even AFMP and an interfence-free movement of the mandible against the maxilla (Example: Major Comp).* ***D*** *The upper and the lower teeth are cuspless and were positioned in the laboratory against a callot. If this is done consequently, the AFMP angle is zero or even negative on both sides. If we use the anatomical variant "B" it is easy to keep the width of the chewing table small, e.g. 6-8 mm. By utilizing such teeth we keep the supporting polygon as small as possible.*

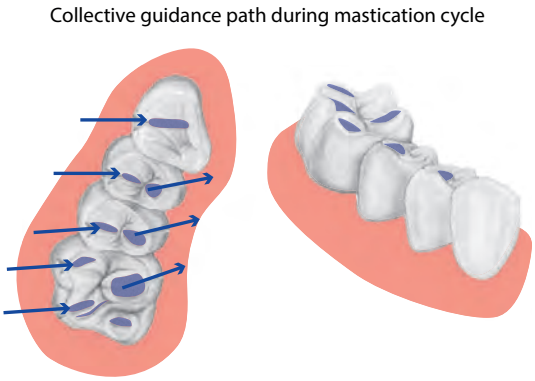

Fig. 5.3 *If the palatal cusps of the maxillary molars and premolars were to guide both laterotrusion and mediotrusion, we would see chewing marks on the teeth, as shown in this drawing. Since the chewing forces in the posterior region are about ten times as high as in the anterior region, massive overuse osteolysis would be expected. One could discuss whether such a situation could be tolerated in a "balanced occlusion", if any. However, this type of guidance is very difficult to achieve and maintain with fixed restorations.*
Advocates of this concept argue that the mandible would not be sufficiently centred if proper support, from a gnathological point of view, was missing. But one might reply that even the presence of complete disorientation of the masticatory system with the aid of a supporting-pin bite registration (e.g. Zentrofix), a reproducible result can always be achieved if only the masticatory force applied by the patient is large enough.

Fig. 5.4 *Advanced abrasion of the posterior teeth in a patient with a natural carnivorous diet, without any dental restorations. Teeth without cusps (but correctly adjusted from the point of view of mastication) have an enormous advantage, namely that they are hard to deflect unfavourably by laterotrusive forces.*

5.5. Some basic considerations

When the occlusion is adjusted at the end of a rehabilitative procedure, our mechanically oriented way of thinking assumes that the jaw joint performs a hinge movement at least toward the end of the jaw closure movement. This is what all the textbooks say – and yet it is wrong. Hinge movements exist only in articulators. The temporomandibular joint performs sliding lateral or anterior movements on the descending path of the articular tubercle of the zygomatic bone. Since the two temporomandibular joints do not have a common axis of rotation (rather, they are arranged at an angle to each other), that assumed hinge movement is impossible anyway. The state of affairs is immediately obvious to any mechanic, but academically trained dentists unfortunately do not want or are unable to understand the simple principle, putting their unfailing faith into the "hinge axis story" instead.

For inexplicable reasons and as a result of boundless fantasies circulating at our universities, the so-called science of "gnathology" has been introduced into our profession. At this point, we do not intend to doubt or deny that a certain level of precision is necessary in our profession. But gnathological precision in a setting of "tripodization" of the occlusion will already produce more damage than benefit in the medium term. Section 2.3 describes this in more detail. Gnathology is based on several false assumptions, such as:

- If we only fixate the bite precisely enough (tripodization), it will remain stable. The truth is that teeth are not immovably fixed in a concrete-like bone. Rather, the external outlines of the bone are subject

to continuous remodelling, and the same is true of the internal structures of the bone. So if we could really fixate teeth in space using "gnathological methods", either the bone would shrink away from the teeth over time, or the teeth would (if rigidly attached to the changing bone) soon move apart from each other. There would be no longer any contact between the maxillary and mandibular teeth, or at most a single point of contact between both jaws.

Our profession has developed different terms and concepts that describe the relation of maxillary and mandibular jaw on closure.

In the dentate jaw, the occlusion determines the position of the temporomandibular joints; the mastication surfaces dominate, and the joints must follow suit as far as possible. We recommend describing the situation with the term **occlusal centric**. Only the muscles are capable of modulating the positions of the joints quickly and at any time. The temporomandibular joints are characterized by a fibrous structure (something that is unique to these two joints). Unlike hyaline joints, they can change their shape over time. They can increase their volume, change position by apposition, or flatten out.

The guiding function of the muscles depends on what time of the day it is and how we feel at that particular point. Given more or less passive jaw closure, the relative to positions of the dental arches will vary even during a single day. As soon as the jaws are firmly closed, each individual will present with a defined joint position, a position we will call **joint centric** for the sake of simplicity.

Ideally, the joint centric and the occlusal centric will coincide, which is the goal of any treatment with immediately loaded implants. However, this goal is associated with a number of problems:

- We cannot know whether the muscles are already located in the ideal joint centric at the end of the treatment and after the insertion and adjustment of the fixed restorations – or whether they have yet to move there. These are short-term or very short-term changes, but unfortunately not short-term enough for us to take them into account or even perceive them as we deliver a fixed restoration.
- With the onset of normal masticatory function, the masticatory forces will change in many cases; usually they will increase, changing the joint centric to a greater or lesser extent.

5.6. Definition and explanation of some terms

5.6.1 Contacts in occlusion

- Occlusal contacts on horizontal surfaces of the antagonist tooth
- Occlusal contacts on sloping surfaces

The following terms do not actually have any bearing on our work and can safely be disregarded:

Cusp-to-cusp contacts or marginal-ridge contacts: under normal circumstances (Angle class 1), cusp-to-cusp contacts should only be present in the lingual cusps. Three to four of these occlusal contacts per side are sufficient.

The term "lingualized occlusion" refers to a situation in which all supporting occlusal contacts are with the lingual cusps of the mandibular posterior teeth.

5.6.2 Chewing marks during mastication

- in canine guidance
- in group function

Undesirable chewing marks may be present on the lingual cusps of the mandibular molars and premolars.

5.6.3 Possible undesirable concept during protrusive movements

- Anterior-to-anterior tooth contacts during protrusion
- Dominant contacts between mandibular premolars and maxillary canines during protrusion
- Dominant distal contacts during protrusion (with and without loss of anterior tooth contact); such contacts can be present almost unnoticed on the technical abutments or in the area of the antagonist teeth.

5.7. Adjusting the occlusion

The patient is instructed to close after thick articulation paper has been placed between the teeth on both sides. Only a strict and simple closing movement is permitted at this point. The patient is asked on which side the first contact occurs. Many patients (but by far not all) can answer this question confidently and correctly. However, contacts on sloping surfaces impair the result, because such contacts are present during occlusion, these contacts will almost always deflect the mandible slightly laterally or medially, which is perceived by patients as the "first contact". In other words, unlike with teeth, where the patient

can distinguish between contacts on slopes and vertical occlusal contacts, patients can always never correctly make this distinction with implant-supported bridges.

Therefore, all visible contacts on slopes must be removed first or existing slope contacts must be converted to occlusal contacts by backfilling with composite, which is particularly recommended if a loss of vertical dimension would be expected if the adjustments were to be strictly subtractive.

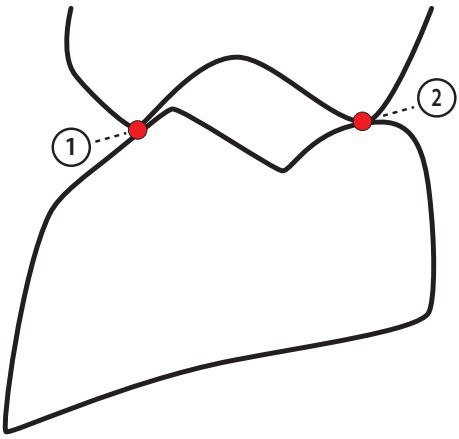

Fig. 5.5 a *A slope contact on the mandibular vestibular cusp (1) is perceived by the patient as "first contact", so these contacts must be removed first. As long as such slope contacts are present in occlusion, any other occlusal contacts (contacts with a horizontal surface) cannot be "trusted", either, with the result that we must expect must the occlusal centric and the joint centric not coincide.*

In accordance with the concept of lingualized occlusion, these occlusal contacts on vestibular cusps of mandibular premolars and molars are not acceptable in any situation.

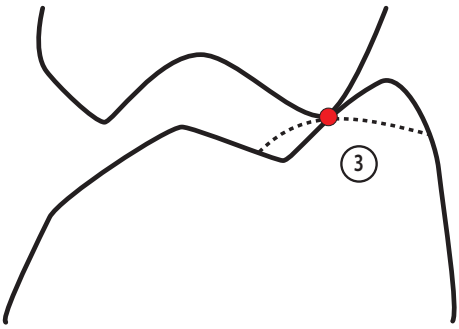

Fig. 5.5 b *A slope contact on a lingual cusp (3) can be corrected by lingual grinding combined with build-up of the cusp with composite in the area of the central fissure. A composite build-up is indicated where no further vertical reduction is desired. At the same time, the more lingual part of the cusp is reduced vertically. Before correction, the mandibular molar would also produce a Wilson curve at variance with the treatment goal.*

5.8. Adjusting the masticatory function

As soon as a stable occlusion has been achieved, i.e., as soon as the patient occludes on both sides with the premolars and the first molars simultaneously (anterior half), adjustment of the mastication function may begin.

There are two main reasons why a patient may push the mandible forward during laterotrusion:

1. The mandible is protruded if there is a premature contact on one side and the jaw "searches" for the contact further mesially on the opposite side. The involuntary preclusive movement indicates that a stable occlusal position relative to the maxilla, a position that is identical on both sides and simultaneously achieved, has not yet been found for the mandible.
2. In addition habitual protrusive movements are observed even with a correctly adjusted occlusion if the maxillary and mandibular frontal groups make contact too easy during laterotrusion. Typical premature contacts are found on the distopalatal corners of the central and lateral anterior teeth. They massively change the chewing pattern because they restrict unimpeded laterotrusion. As long as this is the case, i.e., as long as the mandible moves forward during laterotrusive movements, the masticatory function cannot be adjusted. The correct relation between the maxillary and mandibular anterior teeth must be achieved first. There are several options for doing this:
3.
   - Raising the bite
   - Shortening maxillary or mandibular anterior teeth
   - Adjusting the mandibular anteriors from vestibularly and the maxillary anteriors from palatally or shortening of both sets of interiors.

The main criterion for deciding whether we can adjust the **bite subtractively by grinding** or have to **additively build them up** is whether static or functional anterior tooth contacts might result from grinding (i.e., reducing the vertical dimension in an undesirable way) and whether this must be prevented by increasing the vertical dimension.

The **aim of adjusting the masticatory function** is to achieve bilateral, uniform occlusal surfaces or chewing paths that are used with equal frequency on either side.

Anterior or unilateral chewing patterns must be avoided as they may overload the peri-implant bone on the working side. Contacts on the balancing side, as well as local osteoporosis induced by tensile forces

on the balancing side, may also result in implant mobility. The longer the implants had previously been integrated, the less likely it is that such improper loading will actually lead to mobility. Long integrated implants tend to fracture rather than become mobile as a result of overload osteolysis.

The most important aspects that govern the ability to chew bilaterally with equal frequency include:

- The presence of an identical number of teeth, i.e., the same overall length and width of the mastication surfaces, with uninterrupted rows of teeth in both jaws (no gaps)
- The creation of a bilaterally identical AFMP
- The prevention of any anterior masticatory function by creating a sufficient distance between the maxillary and mandibular anteriors (during occlusion and mastication). 2 mm of overjet and 0.5 mm of overbite are regarded as favourable by most clinicians who use this procedure.

5.9 Variations of the adjustment procedure for existing anterior teeth in both jaws

A special situation occurs when the patient has anterior tooth contacts on natural teeth, i.e., when only partial bridges are present in one or both jaws. There are two treatment options for these cases:

5.9.1 One is to leave the natural anterior contact in place:

- The **advantage** of this approach is that it is possible to adjust the posterior segments to slight infra-occlusion and to create a canine guidance that protects the implant-supported bridges from lateral displacement.
- The **disadvantage** of this approach is that it is highly unlikely that the occlusion (and thus the masticatory function) will be adjusted to a position in which the occlusal centric corresponds to the joint centric. With the help of a supporting pin registration, one could determine whether the joint centric is also present (coincidentally) in natural intercuspidation of the anterior teeth.

If the tooth positions shift at a later point (i.e., if the assumed protection of the patient's stable natural teeth disappears), the stability of the joint position will in all probability also decrease. The mandible can move in the direction of the (muscularly modulated) joint centric (or in any other direction), which prompts changes in the occlusion and requires readjustment of the occlusal surfaces. Thus, despite the presence of "natural" canine guidance and "natural" contacts between the max-

illary and mandibular anteriors, we cannot be entirely sure that everything will remain as stable as assumed or that the bite will be correct or stable at the end of the treatment phase (i.e., in the "natural" mandibular position).

5.9.2 As an alternative, the bite can be slightly raised:

- The anterior teeth will then no longer be in contact, at least on closing, and the occlusion and mastication surfaces will be adjusted in the lateral segments only. This will always take place in a new (usually more retral) position of the mandible, where the earlier anterior contacts (even with the lowered bite) can hardly occur anymore.
- The **advantage** of this approach is that the occlusion centric can be adjusted to match the joint centric.
- The **disadvantage** of this approach is that it is doubtful, especially during the first few months, whether there will be any changes in the joint centric (given that the joint centric is also a muscular centric), which is why close monitoring of the situation and multiple adjustments of the occlusion and mastication surfaces will become necessary.

With a patient who had exhibited an anterior chewing pattern for many years and who mainly used the anterior teeth in both jaws for eating one can be 100% certain that the TMJ position will be displaced anteriorly. Once the new restoration is in place, the same patient will exhibit a much further dorsally located joint position. Moreover, the definitive dorsal position of the joints is not reached immediately, which is why frequent checks (e.g., every two to three weeks) are initially required before a stable occlusion can be achieved in joint centric.

Unfortunately, partial bridge segments are less resistant to improper loading than full-arch bridges, which is why they have to be adjusted with particular precision and at short intervals.

5.10 Adjusting the protrusion and biting function

The next function to be adjusted is the protrusion function. The objective of this treatment step is to achieve interference-free end-to-end anterior tooth contact during biting. It is best to have all four incisors participating in this process, as this distributes the forces over four teeth and reduces the risk of individual facets fracturing under overload.

In order to reach the goal, the maxillary and mandibular anteriors must be shortened regularly, a procedure that (if only a single jaw was restored) also affects the "natural" anteriors. It is recommended to shorten the actual teeth that are "at fault" (i.e., too high), even if they should

happen to be natural teeth. To the extent that first premolars make contact with the maxillary canines during protrusion, these contacts must also be removed.

Further interferences can be generated by the distal technical abutment of mandibular bridges, which is why these parts of the restorations must be closely checked. If they are allocated, they may make contact with the distal aspects of the maxillary first molars on protrusion and interfere with protrusive (but also laterotrusive) movements.

5.11 Why do the occlusion and mastication surfaces have to be adjusted repeatedly – sometimes in one and the same session?

The first paragraph of this chapter had mentioned that occlusion, mastication and protrusion must be adjusted in exactly this order. Any change in the masticatory function affects the interaction of the muscles, and it must therefore be expected that an occlusion initially adjusted "correctly" will suddenly change during further adjustments of the masticatory function. This can be caused, for example, by a unilateral or bilateral backslide of the TMJ towards an "even more" correct joint centric.

Of course, we try to avoid this situation (e.g., by not providing a provisional restoration for at least one day after implant placement). Nevertheless, a correct and permanently stable bite can never be registered with certainty – in any patient.

Medium-term changes in occlusion are to be expected when chewing forces have to be rebuilt, and this takes several weeks or months. Until this has happened (in accordance with the new functional requirements after delivery of the restoration), no stable occlusion can be expected, and mastication paths will change accordingly.

5.12 Functionally generated paths (FGPs), Bennett angles, axial inclinations: how to record pathologies professionally

An incorrigible group of dentists, especially gnathologists, have become accustomed to meticulously registering pathologies of the temporomandibular joints in order to programme articulators individually. This will of course simply enable them to replicate pre-existing pathologies in their shining new restoration.

From our point of view, this approach is not at all helpful. It is absurd, even dangerous. This is because the patient would benefit more if we

were to set up a symmetrical masticatory function, which would also allow the anatomical structures of the TMJ to align and assume a symmetrical shape over the years. If we programme the old deviations and pathologies back into the new dental work, sooner or later undesirable unilateral chewing patterns will (re-)develop.

The only understandable reason why the dentist would want to determine the horizontal inclination of condylar guidance and the Bennett angle and later "set" them individually on the articulator is that they want their planned restoration to provide "balanced occlusion". Even today, some practitioners still consider the antiquated concept of "balanced occlusion" a desirable treatment goal. Many others speak of "balanced occlusion" without ever having achieved this goal. Experience has shown that creating a balanced occlusion is not necessary for our implantological approach using immediately loaded strategic implants because it does not offer any recognizable benefits.

5.13 Therapeutic aspects

When patients complain of pain in distal teeth or on distal implants, the first thing we should think of is muscle-related pain. Only in very rare cases do strategic implants really cause the perceived pain. In most cases, the "pain" originates from the masseter, i.e. at the lower part of the M. masseter (near the angle of the mandible) or at the anterior edge of the oblique ascending part of that muscle. In either case, palpation of these muscular regions will induce pain and this shows the origin of the problem. The anterior edge of the masseter muscle will exhibit hard tension (compare with the anterior edge of the contralateral side), and painful hard knots (myo-geloses) will be palpable at the anterior edge of the muscle and mandibular angle (a certain sign of myo-gelosis). The simple therapy consists of a ten-minute self-massage performed by the patient six times a day. The patient is instructed to massage these areas at the strongest tolerable pressure of the fingers (against the bone base). At the point of attachment of the muscle, the finger pressure must be directed toward the underlying bone. While the oblique ascending muscular part is massaged, one finger must be in the mouth and the other outside it.

After this besides, the muscles will be more relaxed immediately. This treatment does not address the incorrect bite (which remains to be treated), but it alleviates the symptoms, and the situation will be more acceptable to the patient because of reduced or disappearing pain as the patient develops an understanding of the cause of the problem and performs self-massage.

5.14 Observation of the closing movement and palpation of muscle strength and muscle sequence

The occlusion can also be palpated by way of the masseter muscles. To do so, the patient is instructed to slowly open and close, then press the teeth together. The best position for palpation is from the back of the treatment chair while sitting upright. A dentist who routinely performs this examination on all patients will get a good and accurate feel for the functional status of this muscle. It is amazing to note how many patients will not have muscles which are equally strong on both sides and how often the two muscles will not work simultaneously or at the same speed.

In a healthy situation:

- Both muscles must react at the same moment.
- Both muscles must swell to the same size/strength in the final stage (pressing). If patients exhibit twitching of one or both masseter muscles during closing, this means that the occlusal contacts are not reached concurrently on both sides of the jaw or that the occlusal situation is not stable.

Here, the Tekscan® is used to register the occlusal situation at the end of the initial treatment. The results obtained with this device can be recorded digitally or in the patient file so they can be compared with the results and subsequent examinations. This diagnostic measure also promotes the learning process of the treatment provider, who will notice that the change patterns that are present are often similar.

5.15 “Sound check”

When patients close at maximum speed, their teeth will produce a clicking sound as they meet. If the occlusion is correct (i.e., all teeth make contact at the same time), a rich clicking sound will be heard, as when two pebbles meet. This tone also indicates that the brain allows this closing movement to be performed without delay. Such a rich clicking sound should be perceptible at the end of a successful round of occlusal adjustment. The opposite of this desirable sound is a staccato sound that is heard when multiple contacts occur in close succession with minuscule intervals between them. This sound corresponds to the sound we can produce when we touch a tabletop “simultaneously” with all fingers of one hand (as with drumsticks). If we hear such a sound emanating from the mouth, we know for certain that some of the contacts we perceive visually occur earlier than others.

This staccato sound indicates that a stable and uniform occlusion has not yet been achieved. So you must continue asking the patient on which side and in which region the first contacts occur.

The process of closing the mouth is controlled by a complicated neuronal system. If one or two significantly premature contacts exist or if reaching the occlusal centric requires leaving the joint centric and the functional symmetry of the joint, the sound will be less rich, because the brain cannot co-ordinate this type of rapid mouth closure, controlling for all kinds of deviations, in a flash. The control unit of the masticatory system (i.e., the motor centre of the brain) will try to avoid overloading individual areas. Therefore, the occlusion position is not reached as quickly as what we see in simple and safe jaw closure where the function of the masticatory muscles is simultaneous (symmetrical) and undisturbed.

5.16 Eliminating functional blockage

The biblical tale of the healing of Lazarus, who had been paralysed for many years and was suddenly relieved of his paralysis at Jesus' behest, and was then able to stand up immediately and even take his bed with him, gives a dentist charged with the adjustment of the bilateral chewing function in a patient with a unilateral chewing pattern and complete functional disorientation (functional type ***D***) pause for thought.

Unfortunately, the normalization of the chewing function at the end of rehabilitative treatment is often not as easy as it is was for Jesus in the Bible, even though our patients are not paralysed.

Patients who have long been used to blockages which stop the lateral movements (e.g., the AFMP was much steeper on one side than on the other or the chewing function was generally unilateral) do not learn to avail themselves of their new options within seconds or minutes after the blockage has been removed. As long as they do not use the new guidance provided by the new restorations, we will not be able to either correct or control the situation. This means that even if such blockages were removed, the patient would not (or not immediately) make use of the extended movement possibilities. A typical example is that of the patient who had had a unilateral chewing pattern for many years (due to tooth loss on one side) and who still does not seem to be using the newly restored side. Persuading the neuronal control to do new things can take some time, several correction sessions, in other words: a lot of patience.

5.17 Summary

Today, the implantologist's work with the Strategic Implant® is completely standardized. This applies not only to the surgical procedures, which are based on well-defined methods of implant placement at specific skeletal locations; standardization has also reached the prosthetic procedures. The relative position of the occlusal contacts depends on the bite and the relative position of the dental arches, but is otherwise always the same, and is aligned pursuant to the concept of lingualized occlusion. Bilateral simultaneous occlusion and symmetrical chewing paths will ensure that there can be no unilateral overloading of the bony integuments.

Subsequent follow-ups must ensure that the standardized result described above is maintained or restored by simple corrective measures.

Chapter 6

Maintenance of Good Mastication

6.1. Check Up Procedures

During the check-up appointment we always follow the same check-list

- After asking the patient if he/she feels anything unusual or experiences pain or problems with the prosthetic work-pieces, we first inspect all soft tissues and search for signs of infection.
- We ask the patient where he/she feels first occlusal contacts. Almost all patients will be able to answer this question correctly.
- If we ask the patients whether or not they feel limitation in the lateral movements, many patients will not be able to answer the question correctly.
- During the first two years we will take panoramic pictures every 6 months. After this period we take panoramic pictures only if unexpected events demand radiological exploration.

6.2. Active Corrections

Depending on the dentist's education, personality, age and the socio-economical environment[1], a patient may either receive help on his/her demand (e.g. the dentist reacts to reports of pain or damages), or the patient will be advised to actively approach an arising problem. Often this advice comes at a very early stage and it may not be understood by the patient[2].

An active maintenance is definitely necessary on Strategic Implants, comparable to a preventive oil change in the car. This procedure demands specific knowledge and clear, early identification of developments and potential threats.

1 ...does good performance pay?
2 Sometimes it is difficult to convince patients to undergo an active-preventive treatment. A good example for this is the removal of wisdom teeth: although we all know nowadays that un-removed wisdom teeth are the cause of an overwhelming amount of problems in the oral cavity, we sadly see many wisdom teeth not removed timely (e.g. at the age of 11-13).

The facts are:

- Anterior or unilateral patterns of chewing are the underlying reasons for most and severe problems
- Unfavourable opposing dentitions require corrections in order to maintain treatment success in the treated jaw
- Demand for active intervention during maintenance appointments as soon as undesired developments start to be detectable

Dentists who are not ready to step in early and actively convince the patient of a corrective intervention due to their personality, laziness, or for financial reasons (sometimes accepting that this intervention will not be very profitable for them), should rather not work with Strategic Implants. Those colleagues must understand that they can contribute more to the population's overall dental health if they work on teeth and perform more traditional treatments which were learned in their university education.

6.3. Grinding Mobilized Bridges

When mobilized bridges on Strategic Implants must be steadied, the protocol is similar to that of the bridge installation: bilateral equal occlusion must be achieved first. When the patient's jaws reach centric occlusion the bridge must not move or slip in any direction.

One prerequisite for the success of this therapy is true cortical anchorage of all implants. If this anchorage is missing due to faulty positioning of the load transmitting surfaces of the implant, even excellent repeated adjustment will not help and implants must be replaced.

If the bridge is not only horizontally mobile but also partly or completely vertically mobile, replacing or adding implants must be considered. One of the reasons[3] for this is that there is no safe way to determine the occlusion under these circumstances.

3 The main reason is that if Strategic Implants are vertically mobile, the 2nd cortical must be completely remodelled and changed into bone tissue with low mineralization or even into granulation tissue. Although this is a reversible development, a significant reduction of forces must be reached.

After the occlusion corrections are done and the bridge does not move on occlusion, mastication must be ground. Because the bridge is mobile, we have to fixate it manually while we ask the patient to move the mandible laterally. Afterwards all interferences are ground away until the bridge can move virtually without dislocation of the bridge to any side during masticatory movements.

The best way to secure the position of the circular bridge is to hold it between thumb and index finger, with thumb and finger touching both the gums and the bridge at the same time. This way dislocation of the bridge during mastication can be felt.

The surfaces of the bridge must be adjusted until the bridge does not move at all during lateral movements of the mandible. Frequently a severe re-design of the occlusal and masticatory situation is required to achieve this goal.

As a result the forces around the implant's load transmitting surfaces are reduced and the bone in these areas will increase its mineralization. The implants gain stability quite quickly. This stabilization of the implant occurs because cortical bone *per se* tends to retain a high mineralization level and return to high levels of mineralization quickly. Implants anchored in spongeous bone areas (only) will not gain stability under the same circumstances[4, 5].

After about 8-10 days the adjustment work must be controlled and additional adjustments made, and once more after another 20 days.

If the patient felt pain during mastication, this usually stems from irritation of the periosteum behind (below) the 2nd cortical. This pain should stop by the next control after 8-10 days.

During both controls the stability of the bridge should become significantly better. Note that bone is basically a very fast reacting tissue, and its mineralization (in the cortical) will increase rapidly if the conditions are favourable. Spongeous bone seems to not have the same potential for regeneration.

4 This explains why it is so important to achieve secure cortical anchorage in permanent corticals. Note that corticals of extraction sockets (lamina cribrosa) are not permanent corticals.
5 Note however that also under-loaded bone areas lose mineralization (e.g. tension zones) and also this will mobilize implants if they are situated in such areas.

6.4. Body Statics

Patients showing a visible deformation of their skeletal system are likely to also display asymmetrical function in the masticatory system. Such asymmetries can be diagnosed through scaled full body pictures.

Fig. 6.6a *Horizontal and vertical lines on the door of the treatment room. Placing the patient in front of these lines will give a quick overview of the situation. On these pictures we can evaluate symmetry of the head position, asymmetries of the head, height of the shoulders, arm length, position of the arms, etc. Note that many patients wear unilateral devices within their shoes "to compensate differences in the length of the legs"*[6]*, which of course hardly ever exist.*

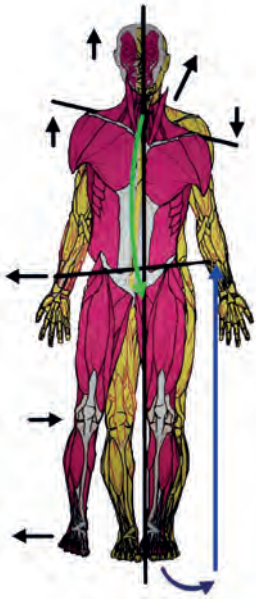

Fig. 6.6b *If the hip is not held horizontally (by the muscles which stabilize the skeleton) many other muscles have to contribute to "compensate" the asymmetry. Often this state is missdiagnosed as "unequal leg length" and "treated" with inserts into the shoe on the side with the "shorter leg". In the vast majority of the cases it is enough to get the muscles relaxed, and the hip will be horizonal instantly, with the legs having equal length again. (This therapy is not advocated and not "recognized" by members of the orthopaedic surgery tribe).*

The described state wastes a lot of unnecessary resources and energy for the affected individual. Although the individual manages to keep the body upright, joints are misloaded and they show degeneration over time and this will then give indications for famous orthopaedic surgery. For more information see www. styfologie-center.ch.

6 After regular growth an individual's feet are absolutely identical in length. Differences in the length of the feet are most often due to a wrong position of the hip in relationship to the spine. These patients can be treated by muscle relaxation in a single appointment. At the end of growth in all individuals the length of the legs is identical on both sides. This functional result cannot be avoided, and long bones do not shrink.

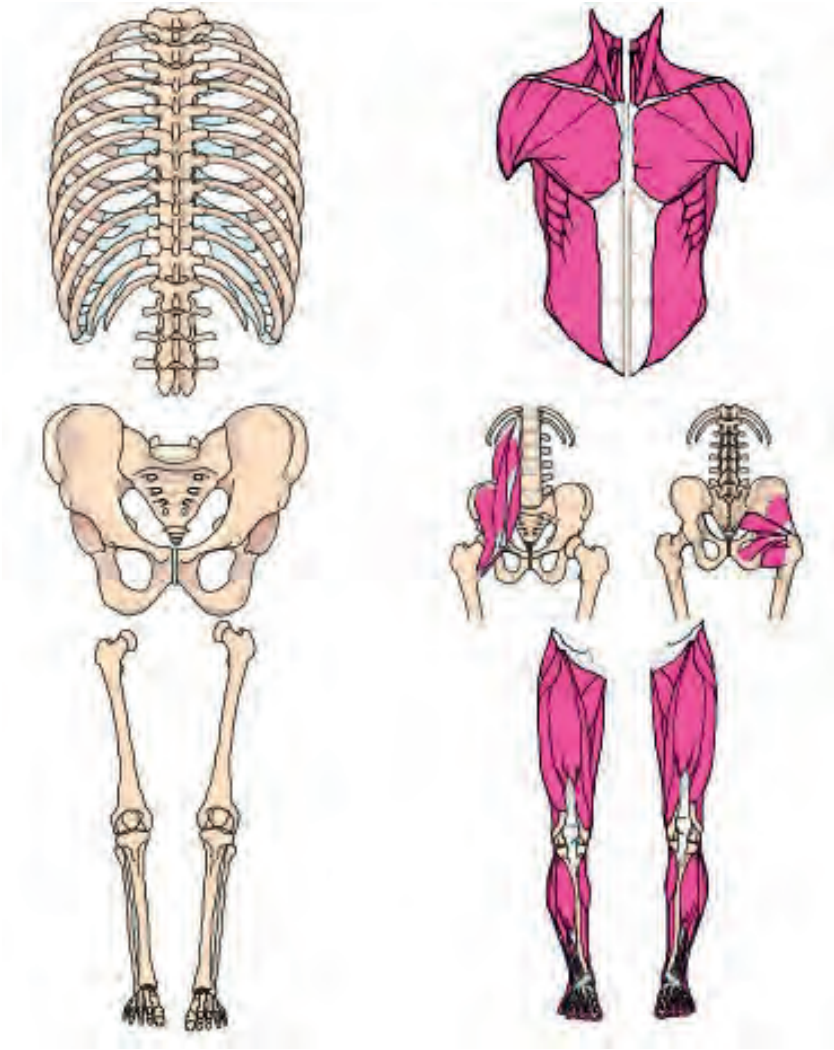

Fig. 6.6c *The pelvis, the middle level, functions as a suspension of the legs and as a support for the upper body.*
An inclined pelvic level means that the upper body is able to walk upright with considerable oblique muscle tension. However this leads to a curvature of the spine and subsequently there is also tension in the neck area and a subsequent change in the head position.
The legs are attached to the pelvis via ligaments and muscles. Lateral pelvic displacements, which can be caused by the oblique pelvis as well as by psychological impairments, are appended, which cause pelvic depression and lateral pelvic relocations that cause changes in the leg position angle. A pelvic rotation can also occur. If this rotation is added to the mispositioning, additional balancing tensions are necessary to maintain the posture.
No skeleton can move on its own, it is the muscle tendons and ligaments that hold the skeletal bones together and move them.
The muscles need the bones to translate their strength. If tension and counter-tension are not in equilibrium in the resting state, then the whole skeleton can avoid these forces only via evasive postures. This also affects internal organs.
These forces of the alternative postures affect the head posture, the relative position of the jaws (to each other) and the chewing movements.

Chapter 7

Tongue Function

The tongue consists of a number of muscles that are able to significantly alter its morphology during all kinds of functions. The possibilities for the motion of the tongue are limited by the mandibular bone, the palate, the tooth arches and the floor of the mouth. While the morphology of the tongue can be altered, the total volume cannot be changed, except through surgery[1].

Fig. 7.1a *The tongue is blocked and dislocated by teeth to the right side of the patient and at the same time the mandible must automatically be dislocated to the left side, both in the rest position and during movements. A symmetrical masticatory function is not possible under these circumstances. The situation is not always as clearly visible as in this picture!*

If the available space for the tongue is reduced, it will slip between the tooth arches, which opens the bite. In more severe cases the tongue will move anteriorly between the lips. Speech function will suffer. Even if the tooth arch of the bridge is in the correct position and not overly thick, patients will have problems speaking. Creating wider arches and raising the vertical dimension are the only possible solutions to the problem and relieve the lack of space. Many speech problems have their origin in the distal part of the bridge arches.

1 The development and soft tissue attachment of the tongue in youth determines the Angle class. A large and active tongue will create a massive mandible of which the teeth will overgrow the occlusal limitation normally provided by the upper jaw's teeth. If the mobility of the tongue is limited by short frenula, the anterior development of the mandible is prevented. As a rule the frenulum of the tongue should be shortened in children (e.g. through electro-surgery) if the patients cannot reach the attachment area of the nose to the anterior nasal spine outside the mouth. Tongue reduction is a routine procedure and typicall improves the patients quality of life significantly.

Fig 7.1b *In this example the tongue is passive in the floor of the mouth. All implants have been placed in the best position from the point of view of optimum bone utilization. The distance between the tongue and individual implants differs. The bridge has to create a symmetrical environment for the tongue. Therefore the bridgearch will not just follow the line of implants.*

Asymmetries in the arches lead to functional problems and difficulties speaking. Bulky lingual or palatal overhangs next to upper and lower first premolars are often the reasons for such problems and in most cases this can be easily corrected in the mouth. These areas are created by the dental technician if they blindly create bridge frames that simply follow the row of the implants regardless of functional needs and tooth position. Grinding implant abutments in order to avoid these abutments creating an obstacle for free tongue movements during speech is a task for the dental technician. Details are explained in booklet 6 of this series.

If whole tooth arches are rotated, the medial and distal internal edges block the tongue function. This may require the new fabrication of the bridge, and typically this problem is solved while the patient switches from the 1st to the 2nd bridge.

If the dental technician works quickly enough, the bridge can be ready on the day following the operation. This allows us to deliver the bridge and secure it with temporary cement (on the most stable implants) or without cement for 1-2 days to test the function.

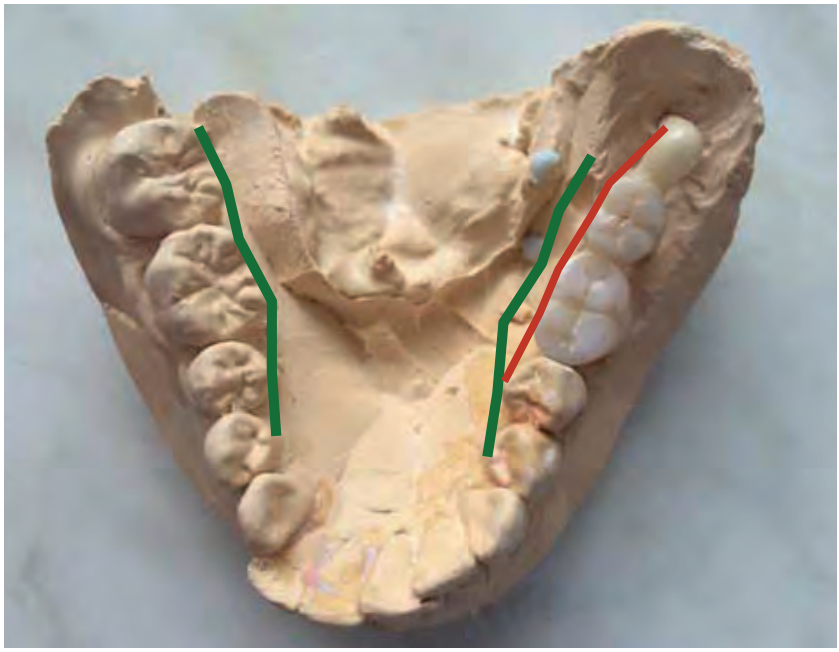

Fig. 7.2 *In this case the distal teeth in the left lower jaw have been replaced by a zirconium bridge on three implants. Although the available tongue space on the operated side (red line) is larger than on the non-operated side (green line on right side, and mirrored green line on left side), it does not mean that the patient is happier. The extreme lingual inclination of the distal dentition on both sides could not be restored on implants, because such a strong off-axis load seemed unacceptable.*
Any asymmetry poses a threat to symmetrical function and if the patient is confronted with this situation, he/she will subconsciously feel insecure. In many cases the patient will not be able to clearly explain what actually bothers him, we have to recognize from our experience where the problem is located.
A clinical situation as created here is acceptable in most cases as the patient adapts. If the patient is permanently bothered we must firstly consider the reason to lie in the asymmetry, and for instance reduce the width of the patient's dentition on the non-operated side. Such grinding will compensate for the extreme lingual inclination of the teeth.

Conclusion

The goals of the treatment for Strategic Implants work are:

- A bilateral equal and symmetrical occlusion
- A bilateral equal and symmetrical mastication, using slope of the teeth 4,5,6
- A symmetrical function of the muscles, especially of the tongue
- Build-up of equal muscle forces on both sides of the mandible
- Identical AFMP angles on both sides
- Disengagement of the group of front teeth in occlusion and mastication

This treatment result must be maintained. This demands frequent controls and pro-active corrections, and it may require increasing the vertical dimension. Because this is easier done on plastic surfaces, we prefer to incorporate metal-to plastic (or metal-to-acrylic) bridges as first prosthetic workpieces during 6-x months post-operatively.

ISBN 978-3-945889-28-2
4447_EN_V059_165x235_08-21

International Implant Foundation Publishing